



# INTERNATIONAL JOURNAL OF RESEARCH IN PHARMACEUTICAL SCIENCES

Published by Pharmascope Publications

Journal Home Page: [www.pharmascope.org/ijrps](http://www.pharmascope.org/ijrps)

## A study to compare the effect of ACL versus ACL and all rehabilitation protocol in subjects with post-surgical ACL reconstruction

Sowmya MV\*, Rahul Dev, Manoj Abraham

Saveetha College of Physiotherapy, Saveetha University, Chennai, Tamil Nadu, India

### Article History:

Received on: 18.09.2018  
Revised on: 19.12.2018  
Accepted on: 21.12.2018

### Keywords:

### ABSTRACT

The knee joint is a hinge variety of modified type of joint. The anatomical structure of the knee joint is formed by the upper part of the tibia and the lower end of the femur through the femoral condyles. The knee joint is supported by many ligaments for the stability of the joint and the ACL serves the most for the stability of the knee joint. ALL ligament which was found that this is structure also plays an important role in the stability of the knee joint, and hence this will, in turn, improve the recovery in the ACL rehabilitation. The study was done in Saveetha medical college and hospital. The sample size was 10 samples undergoing ACL rehabilitation. The duration of the study was 3 months. Inclusion and the exclusion criteria were postulated, and hence the sample was selected based on that for the study. The sample was divided into two groups. The control group received the conventional ACL rehabilitation, and the experimental group received the exercise for the ALL along with conventional ACL rehabilitation. The data were collected and statistically analyzed. The outcome of the treatment depicted that the experimental group has better ROM and Muscle power than the control group. The study concludes that we have both the ACL and ALL management during the ACL rehabilitation then Muscle power and the ROM will increase and improve the stability. Hence this study suggests that we need to have ALL management during the ACL rehabilitation.



### \* Corresponding Author

Name: Sowmya MV  
Phone: +91-9841472619  
Email: [sowmyamv83@gmail.com](mailto:sowmyamv83@gmail.com)

ISSN: 0975-7538

DOI: <https://doi.org/10.26452/ijrps.v10i1.1795>

Production and Hosted by

Pharmascope.org

© 2018 Pharmascope Publications. All rights reserved.

### INTRODUCTION

The knee joint is a hinge type of joint which is complex in structure and function. The knee joint has many ligaments around it which play a very important role in the stability and the mobility of the knee joint. The ALL is the secondary restraints of the ACL. The knowledge about the structure and physiology among the researcher, physician, surgeon and the physical therapist has increased

swiftly. The previous studies have shown that ALL plays a very important role in rotatory instability and the pivot shift in the knee joint (Claes S *et al.*, 2011). There are many research paper being published on the ALL, though huge research is done there is no proper insight into the existence of ALL. After an idea about the ALL spread, there were many surgeons from orthopaedics who showed their keen interest in the further exploration on the ALL ligament function on the knee joint. The literature review shows that there are more than 80 studies which are done on the ALL ligament supporting its existence and its role in the function of the knee joint, but still, there is no proper insight about the ALL structure and its function. We can say that ALL is the controversial subject. Some author states that there is the presence of this structure and some author say that the structure does not exist, and there is no function of the structure in the stability of the knee joint (Kittl *et al.*, 2015, Musahl *et al.*, 2016, Pujol *et al.*, 2007). For some author, there is the existence of ALL structure

when examined macroscopically (Caterine *et al.* 2015, Daggett M *et al.* 2015, Helito CP *et al.* 2013,). The initial observation was made by Sir Paul Segond who was anatomist in France. Sir Paul has published an article "pearly Fibrous resistant band" which said that there was a high amount of tension due to more internal rotation which can cause the avulsion fracture due to the stress of the rotation (Vincent JP *et al.*, 2012). There was an article published by the Hughston *et al.* which said that "middle third of the lateral capsular ligament" is "Technically strong" with "Major lateral static support at around 30 degrees of flexion". This is inserted proximal to the lateral epicondyle of the femur and distal to tibial joint margin (Segond P, 1879). There was anterolateral rotatory instability which is caused due to an injury to this ligament, and this is diagnosed with the help of the "Jerk Test". This ligament will provide passive rotational stabilization of the knee. Based on the previous study the researcher have found that the ALL ligament will cause the avulsion in the plateau of the Tibia. Capsule osseous layer present in the iliotibial tract will function as the ALL (Terry GC, 1993). There are many other Researcher who has done vast research in the field of ALL and have given us their best to provide us with wide knowledge on the function of the ALL in the stability of the knee joint during the rotation. The information on the anatomy of the ALL was well described by the Claes *et al.* and he also described the role in the stability of the knee joint. The morphology of the ALL looks triangular and is situated deep to the iliotibial band. The mean diameter is around 11.85 mm. This study will try to explain the importance of ALL rehabilitation. We normally miss the ALL during the ACL rehabilitation which leads to the failure. This study intends to study the effectiveness of treating ALL during the ACL rehabilitation.

## MATERIALS AND METHODS

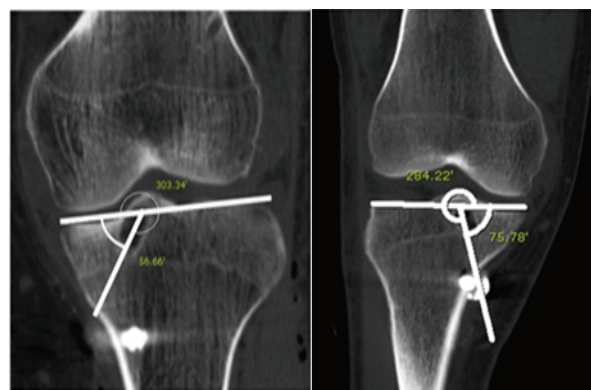
This study was done among the 20 patients who were screened with an ACL injury in the outpatient department of saveetha medical college and hospital, Chennai, Tamil Nadu, India. The duration of the study was for three months. The study design is a randomized control trial, and sampling technique is a convenient sampling method. The inclusion and the exclusion criteria were postulated as per the study, and the samples were selected for the study. The criteria for inclusion was that the subject should be post-operative ACL surgical repair, Non-obese patients, No congenital deformity, No history of recent fracture. After the selection of the samples for the study, there were randomly divided into two groups as the experimental group and the control group. The control group was given the ACL rehabilitation, and the other group (exper-

imental group) received the ACL and ALL rehabilitation. The ACL Rehabilitation along with ALL is mentioned. The outcome of the tibial tunnel from the X-ray was measured. The most common method for the measurement of the Tibial tunnel is by using the Amis and Jakob line (Figure 1). This line will pass through the posterior corner in the medial plateau of the tibia (Amis AA *et al.*, 1998). The goniometer was used to measure the ROM (Range of motion) of the knee joint, and the muscle power was evaluated using the manual muscle testing. The lower extremity functional scale was used to evaluate the functional status of the lower extremity. This is the questionnaire which contains 20 items and is scored on 5 point scale. All the points are added in the end; the score may vary from 0 to 80 in which 80 indicates the highest functional status.

## RESULTS AND DISCUSSION

The Range of motion was measured using the manual goniometer, and the manual muscle testing was done as per the MRC grading for hamstring and quadriceps which is presented in table 1. Amis and Jakob's line was used to measure the tibial tunnel which is given in table 2. The functional status of the lower limb was measured using, the lower extremity functional scale which is in table 3.

The objective of the study was to find the effectiveness of ALL management during the ACL rehabilitation to improve the functional mobility and to prevent further complications. The study depicts that the group which received the ALL and ACL management both has better improvement than those who just received the ACL management.



**Figure 1: Radiographic measurement of tibial Tunnel**

## CONCLUSION

This study significantly proves that ALL ligament exists and there is the definite role of ALL ligament in the stability of the knee. This article shows that the combined ACL and ALL management will speed the recovery and increase the mobility and stability in the knee. This will reduce ACL reconstruction

**Table 1: Results for the ROM**

Group	Range of motion	
	Pretreatment (mean)	Post-treatment (mean)
	Flexion	Flexion
Control group	70 degree	100 degree
Experimental group	70 degree	110 degree

**Table 2: Results for the muscle strength**

Group	Muscle strength			
	Pretreatment (mean)		Post-treatment (mean)	
	Quadriceps	Hamstring	Quadriceps	Hamstring
Control group	2 <sup>nd</sup> grade	2 <sup>nd</sup> grade	3 <sup>rd</sup> grade	3 <sup>rd</sup> grade
Experimental group	2 <sup>nd</sup> grade	2 <sup>nd</sup> grade	3 <sup>rd</sup> grade	3 <sup>rd</sup> grade

**Table 3: Angle of tibial tunnel measurement**

Group	Pretreatment	Post treatment
Control group	57.56	61.54
Experimental group	56.32	65.43

**Table 4: lower limb functional scale**

Group	Pretreatment	Post treatment
Control group	52	67
Experimental group	52	73

failure. Therefore, it is worth integrating ALL management during the post-operative ACL rehabilitation.

## REFERENCES

Amis AA, Jakob RP, 1998, Anterior cruciate ligament graft positioning, tensioning and twisting, *Knee Surgical Sports Traumatology Arthroscopic*, 1: S2-S12.

Caterine S, Litchfield R, Johnson M, Chronik B, Getgood A, 2015, A cadaveric study of the anterolateral ligament: re-introducing the lateral capsular ligament, *Knee Surgical Sports Traumatology and Arthroscopic Of Jesska*, 23(11):3186-3195.

Claes S, Vereecke E, Maes M, Victor J, Verdonk P, Bellemans J, 2013, Anatomy of the anterolateral ligament of the knee, *Journal of anatomy*, 223(4):321-328.

Daggett M, Ockuly AC, Cullen M, Busch K, Lutz C, Imbert P, Sonnery-Cottet B, 2016, Femoral origin of the anterolateral ligament: an anatomic analysis. *Arthroscopic journal of America*, 32(5):835-841.

Helito CP, Demange MK, Bonadio MB, Tirico LE, Gobbi RG, Pecora JR, Camanho GL, 2013, Anatomy and histology of the knee anterolateral ligament, *Orthopedic Journal of Sports Medicine*, 1(7):2325967113513546.

Ingham SJ, de Carvalho RT, Martins CA, Lertwanich P, Abdalla RJ, Smolinski P, Lovejoy CO, 2005, Anterolateral ligament anatomy: a comparative anatomical study, *Knee Surgical Sports Traumatology Arthroscopic of jesska*.

Kennedy MI, Claes S, Fuso FA, Williams BT, Goldsmith MT, Turnbull TL, Wijdicks CA, LaPrade RF, 2015, The anterolateral ligament: an anatomic, radiographic, and biomechanical analysis, *American journal of sports medicine*, 43(7):1606-1615.

Kittl C, El-Daou H, Athwal KK, Gupte CM, Weiler A, Williams A, Amis AA, 2016, The role of the anterolateral structures and the ACL in controlling laxity of the intact and ACL-deficient knee, *American journal of medicine*, 10.1177/0363546515614312.

Monaco E, Ferretti A, Labianca L, Maestri B, Speranza A, Kelly MJ, D'Arrigo C, Navigated knee kinematics after cutting of the ACL and its secondary restraint, *Knee Surgical Sports Traumatology Arthroscopic Of Jesska*, 20(5):870-877.

Musahl V, Rahnemai-Azar AA, van Eck CF, Guenther D, Fu FH, 2016, Anterolateral ligament of the knee, fact or fiction, *Knee Surgical Sports Traumatology of Arthroscopic of Jesska*, 24(1):2-3.

Parsons EM, Gee AO, Spiekerman C, Cavanagh PR, 2015, The biomechanical function of the anterolateral ligament of the knee, *American journal of sports medicine*, 43(3):669-674.

Pujol N, Blanchi MP, Chambat P, 2007, The incidence of anterior cruciate ligament injuries among competitive Alpine skiers: a 25-year investigation, *American journal of sports medicine*, 35(7):1070-1074.

Rasmussen MT, Nitri M, Williams BT, Moulton SG, Cruz RS, Dornan GJ, Goldsmith MT, LaPrade RF,

2016, An In Vitro robotic assessment of the anterolateral ligament, part 1: the secondary role of the anterolateral ligament in the setting of an anterior cruciate ligament injury. *American journal of sports medicine*, 44(3):585–592.

Terry GC, Norwood LA, Hughston JC, Caldwell KM, how iliotibial tract injuries of the knee combine with acute anterior cruciate ligament tears to influence abnormal anterior tibial displacement, *American journal of sports medicine*, 21(1):55–60

Vincent JP, Magnussen RA, Gezmez F, Uguen A, Jacobi M, Weppe F, Al-Saati MF, Lustig S, Demey G, Servien E, Neyret P, 2012, The anterolateral ligament of the human knee: an anatomic and histologic study, *Knee Surgical Sports Traumatology Arthroscopic Of Jesska*, 20(1):147–152.