



# INTERNATIONAL JOURNAL OF RESEARCH IN PHARMACEUTICAL SCIENCES

Published by Pharmascope Publications

Journal Home Page: [www.pharmascope.org/ijrps](http://www.pharmascope.org/ijrps)

## A serological and histological study of *Passer domesticus* infected with *Toxoplasma gondii* parasite

Adel Jabbar Hussein\*<sup>1</sup>, Hiba Riyadh Jameel Al-abodi<sup>2</sup>, Rana Imad Al\_Mashhadany<sup>3</sup><sup>1</sup>Anatomy and histology department, College of veterinary medicine, University of Al-Basrah, Iraq<sup>2</sup>Department of environment, college of sciences, university of Al-qadisiyah, Iraq<sup>3</sup>Clinical and laboratory sciences department, Pharmacy college, University of Al-Basrah, Iraq

Article History:	ABSTRACT
Received on: 16.10.2018 Revised on: 22.12.2018 Accepted on: 25.12.2018	<p><i>Toxoplasma gondii</i> parasite has three contagious stages: the oocytes, which is introduced into the external environment with the faeces of the infected cats, which later form the spores. The current study depended on detection of antibodies by using the serological tests such as latex, and rapid cassette testing are widely used to diagnose toxoplasmosis due to their ease of use and low cost, as well as the lack of time and effort required to perform them, the result of the test is shown after 3-5 minutes and depends mainly on efficiency and accuracy is one of the tests used in the epidemiological studies of toxoplasmosis in birds, in particular, local chickens and pigeons, the results of the rapid cassette test used to examine 80 samples of a serum taken from bird <i>Passer domesticus</i> showed that the total infection rate in this species of <i>Toxoplasma gondii</i> parasite was 71.25% with 57 positive samples out of a total of 80 samples. It was also observed that the presence of IgG antibody was (7.01%) with 4 positive samples while IgM antibody (5.26%) was positive (3 positive samples), the highest IgG + IgM antibody was 62.5% (50) , In the study of histopathological changes in <i>Passer domesticus</i> members, the presence of Lesions lesions associated with infection in both the liver and the small intestine was characterized by the presence of congestion in the blood vessels, as well as the expansion of the jibaniat with the loss of the engineering structure of the liver. In the tissue with a degenerative degeneration.</p>
<b>Keywords:</b>	
Toxoplasmosis, Serological methods, Al-Basrah	



### \* Corresponding Author

Name: Adel Jabbar Hussein

Email: [Hiba.alabodi@yahoo.com](mailto:Hiba.alabodi@yahoo.com)

ISSN: 0975-7538

DOI: <https://doi.org/10.26452/ijrps.v10i1.1842>

Production and Hosted by

Pharmascope.org

© 2018 Pharmascope Publications. All rights reserved.

### INTRODUCTION

A parasite is a single-cell, microscopic or multicellular organism such as flatworms, capillaries, and nematodes that settle for some time of its life cycle. The body of a larger organism known as the host or host may be a human being or an animal that guarantees food, protection, and shelter. The relation between the parasite and the parasite is

known as parasitism. This relationship involves two extremes, one of which is called parasite and the other is affected. This is called Host. This relationship does not depend on food and shelter, but rather for other purposes such as growth, sexual maturity, and reproduction (Hassan, 2016; Al-Abodi, 2018).

*Toxoplasma gondii* parasite has three contagious stages: the oocytes, which is introduced into the external environment with the faeces of the infected cats, which later form the spores. Tachyzoite, which is rapidly divided into all the host and intermediate host cells, is sometimes surrounded by an irregularly shaped bag The thin layer of the wall is known as the pseudocyst, and the slow-growing Bradyzoite, which proliferates slowly in a thick wall sac known as the tissue cyst, is formed within the different organs of the host's body (Al-abodi, 2017 ; Al-Ammash *et al.*, 2018) . This sac varies in size and shape depending on age, and The injury

occurs as it has an elongated shape in the muscles and is circular or oval in the rest of the organs (Foulon *et al.*, 1999).

As a result of the infection, the lesions of the lesions are accompanied by an inflammatory reaction and Necrosis in the organs, leading to symptoms such as anaemia, headache, fever, and pain in the muscles. The disease can cause complications that destroy cells in the various organs of the host's body such as the brain, Liver and heart, and sometimes the central nervous system. The disease may become chronic, accompanied by the rapid multiplication of fast-paced hippocampal tissues and the formation of tissue cysts containing the slow-growing moulds that remain in the tissues for several years without any clinical symptoms (Simpson, 2002).

## MATERIALS AND METHODS

### Collecting bird samples

80 birds *Passer domesticus* were collected periodically by hunting those birds from different areas of the Al-Basrah governorate and during the period from March to July 2017

### Collection of blood samples

Blood samples were removed from 80 intravenous vesicles in the area under the wing of *Passer domesticus* by means of Syringe syringes of 5cc size. Sturkie, 1965, and at 3.55, blood samples were placed in steroid-free sterile anticoagulation test tubes for serum test, the number of birds and the date of collection of the sample and then brought to the laboratory parasites in the Laboratory of College of Veterinary / University of Al-Basrah, the serum extracted by centrifuge 3000 cycles/min for 5 minutes, the serum is then removed by a sterile pipette and placed in other sterile tubes with the bird number and the date of separation. The samples were kept at -20 ° C until the test was performed.

### Diagnosis Methods

#### Rapid Test Cassette (Toxo-IgG / IgM)

##### A) The Samples

Use the previously separated and frozen serum at -20 ° C where samples were extracted and left until room temperature was reached (Al-Abodi, 2018).

##### B) Test Procedure

1. The frozen serum samples were taken out and left until reaching the room temperature.
2. The sample of the serum should be gently washed before use

3. The test instrument was extracted from its cover and placed in a flat and clean place
4. The sample number ID to be checked on the tool was recorded
5. The plastic droplet with the test kit (Appendix 29) is filled with 90-60 microliters (3-2) drops of serum, avoiding an air bubble while the serum is removed. The serum is placed vertically in the hole in the tool, 90 µl- 60 of the dilution sample is then placed in the tool hole as well
6. The result is read within 15 minutes of placing the components in the hole.

### Study histopathological changes stud

Histopathological changes were studied using the histological segments presented by the sectioning section described by Bancroft & Stevens (1982).

### Preparation of histological slides

#### A. Washing Washing

The extraction of the samples consisted of a fixed solution (formalin 10%) and washed with ethyl alcohol with 70% concentration to remove the fixer.

#### B. Anacaz & Thrilling Clearing & Dehydration

The water was withdrawn from the samples by an ascending chain of ethyl alcohol (95%, 90%, 80%, 70%, 50%) and for 2 hours at each concentration.

#### C. Impregnation impregnation

Paraffin Wax wax was used with a melting point of 58 m. This process involved modelling with a mixture of xylene and 1: 1 molten wax for a half hour. The models were then impregnated with waxed wax for half an hour and several changes to ensure that the sample was fully paraffin waxed.

#### D. Landfill Embedding

Wax moulds were made on samples of the installed samples by pouring molten wax into special plastic moulds, where the samples were embedded and left until the wax hardened and then separated from the moulds and stored in a cool place until cutting.

#### E. Trimming Trimming

The sample moulds were analysed using a sharp blade to remove the excess wax. The rotating microtome was then fixed on the base of the rotary microtome. The models were cut with 5 microns. The sections were loaded on glass slides after the brushing process, and the slides were placed on the hotplate at a temperature of 40-53 m. Fabric brushes, drying and dissolving wax.

**Table 1: Types and percentages of antibodies of *T. gondii* in *Passer domesticus* bird using the rapid cassette test**

		Ig type		Positive total (%)	Total number	The sample
IgG+IgM	IgM	IgG				
Total number (%)	Total number (%)	Total number (%)				
50	3	4		57	80	<i>Passer domesticus</i>
62.5(b)	5.26(a)	7.01(a)		71.25		

#### F. Pigmentation and loading Staining & Mounting

In order to obtain dyed tissue slices, the wax should be disposed of as a laxative material. The loaded and container slides were placed on sample samples in the xylene for 10 minutes and then passed with a particular concentration of ethyl alcohol (absolute, 50%, 70%, 80%, 90%). For 2 minutes at each concentration and then dyed with hematoxylin for one minute and then washed with tap water for 5 minutes and then stained the Eocene dye for 1 minute and placed one acid in the acidic alcohol and then transferred to an ascending chain of ethyl alcohol concentrations of 95%, 90%, 80% , 70%, 50% (absolute) and for 2 minutes for each concentration and after it was promoted with two zilines 10 minutes and then loaded with Canada balsam adhesive for final installation after the slide lid is placed, and the slides are placed on the dry, hot plate and ready for microscopic examination.

The glass slides were examined using the composite optical microscope. Photographs of the tissue sections were taken using a Sony camera.

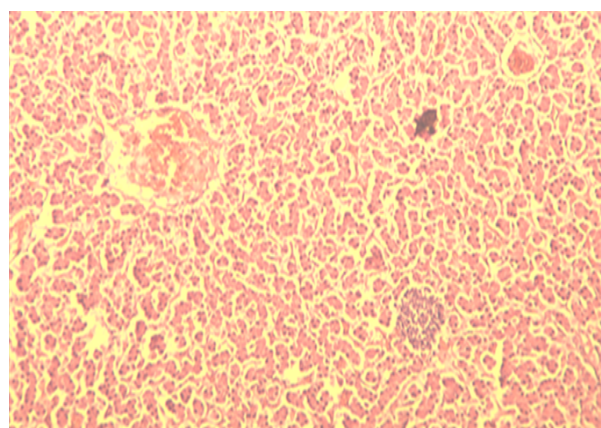
#### Statistical analysis

The data were analysed using SPSS version 10.5 software, where the Square Square-X2 test was used to determine the significant differences below the probability level of P00.05 as mentioned in Niazi (2001).

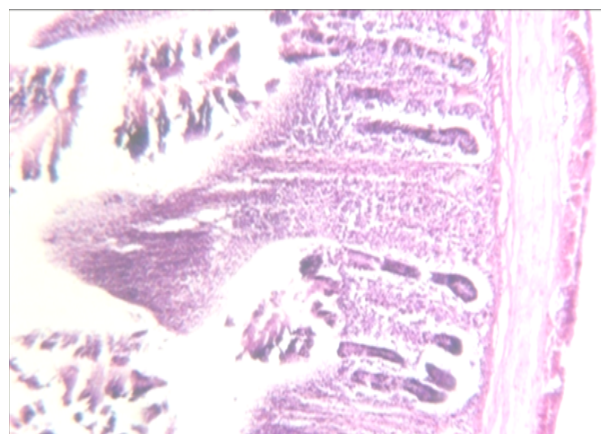
#### RESULTS AND DISCUSSION

Detection of antibodies by using the Serological tests such as latex and rapid cassette testing is widely used to diagnose toxoplasmosis due to their ease of use and low cost, as well as the lack of time and effort required to perform them (Hasson, 2004). The result of the test is shown after 3-5 minutes and depends mainly on efficiency and accuracy (Al-Ghurairi, 2007) is one of the tests used in the epidemiological studies of toxoplasmosis in birds, in particular, local chickens and pigeons (Ali *et al.*, 2005). The results of the rapid cassette test used to examine 80 samples of serum taken from bird *Passer domesticus* showed that the total infection rate in this species of conical parasite was 71.25% with 57 positive samples out of a total of

80 samples. It was also observed that the presence of IgG antibody was (7.01%) with 4 positive samples while IgM antibody (5.26%) was positive (3 positive samples). The highest IgG + IgM antibody was 62.5% (50) Statistical analysis showed that there were significant differences between the presence of the three antibodies in *Passer domesticus* sparrow vaccine as well as MBI N in Table (2).



**Figure 1: A section in a liver infected by a *T. gondii* parasite that detects blood vessel congestion as well as a tissue cyst**



**Figure 2: A cross-section of the small intestine of *Passer domesticus* bird with a *T. gondii* parasite observed hyperplasia in the villus**

The presence of IgG, IgG + IgM and IgM antibodies indicates that acute, chronic or recurrent parasitic infections are present, Khurana *et al.*, (2010)(The incidence of conical parasitic parasites in the periodic spores recorded in this study is higher than that recorded using the latex test by El-massry *et al* (2000), Dubey *et al* (2005a), al-Tai *et al* (2005), Dubey & Shen Al-Ramahi and Alkhaled (2011) with

45.11%, 55.3%, 81.81, 51%, 50%, 59.6% and 47.2%, respectively, and higher than in the study of Sreekumar *et al.*, (2003), Aghwan (2005) and Yan *et al.*, (2009), which accounted for 4.1%, 26% and 17.9%, respectively, using the latex axis.

### Histopathological changes

In the study of histopathological changes in the cyclic sphincter members, the presence of Lesions lesions associated with infection in both the liver and the small intestine was characterised by the presence of congestion in the blood vessels, as well as the expansion of the jibaniat with the loss of the engineering structure of the liver. In the tissue with a degenerative degeneration. It was also noticed that there was a tissue bag for the parasite located near the blood vessel. This is consistent with the findings of all of Al-Kanani *et al.*, (2006) and Amin *et al.*, (2012) and Alkhaled (2012) Hyperplasia of liver cell, It is believed that the reason for the emergence of congestion in the blood vessels is the ability of the colonic parasitic parasite to move and spread through the blood in addition to the ability to release some protein substances that stimulate the platelets and lining cells to the secretion of some chemical media, which helps to adhesion and aggregation of blood platelets and blood components on the walls Blood vessels also work to increase the vascular permeability and thus enter the tissue and stability in the organ (Burney *et al.*, 1999).

While the histological changes in the small intestine were the presence of hyperplasia in the vesicles, this may be due to the infiltration mechanism of the parasite of the intestinal cells leading to apoptosis of the cells in order to get rid of the parasite in addition to the ability of these cells to regenerate quickly, signs of regeneration in irregularly shaped cells are sizes and shapes represented by hyperplasia (Liesenfeld, 2002).

### REFERENCES

- Abed, S. A, 2017. The occurrence of Anatidae in Sawa Lake: A Ramsar Wetland Site in Southern Iraq, Journal of Advanced Zoology, J. Adv. Zool. 38 (1) 43-51.
- Agwan, Sri Salem Abdul Razzaq. (2005). Investigation of some sources of infection with the study of the immunological and pathological effects of the conical curved parasite. *gondii* PhD thesis Faculty of Veterinary Medicine, University of Mosul.
- Al- Canaanite, the triumph of Rahimu Obeid. (2004). Congenital Artery Capability on Events of Oxidative Stress and Inflammation of Erectile
- Al-abodi, H. R. J. (2017). Serological and molecular detection of *Toxoplasma gondii* in *Columba livia* hunting pigeons of AL- Qadisiyah province. *AL-Qadisiyah Journal of Vet. Med. Sci*; 16 (1):128-133
- Al-Abodi, H. R. J. (2018). Suspicion in the form of infection is the basis for selecting the appropriate method for examining the toxoplasmosis disease of bends that have no symptoms from patients. *Int. J. Adv. Res.* 6(9), 655-662.
- Al-Abodi, H. R. J. (2018). Use of rapid cassette test and polymerase chain reaction technique to investigate toxoplasmosis in *Columba livia* birds in Al-Muthanna governorate. Proceeding of 6th International Scientific Conference, College of Veterinary Medicine, University of Basrah, Iraq, *Basrah Journal of Veterinary Research*, Vol.17, No.3: 45-50.
- Al-Ammash, M. S. J.; Al-Shaibani, K. T. M. and Al-Abodi, H. R. J. (2018). Investigating the prevalence of infection with *Toxoplasma gondii* in men and women in Samaraa city, Iraq. *Plant Archives* Vol. 18 No. 2, pp. 2501-2508.
- Al-Ghurairi, Abtahal Jassim Ali (2007). A serological and epidemiological study of toxoplasmosis in Diyala Governorate. Master Thesis. The University of Diyala. Faculty of Education.
- Al-Grawi, E.D.C., and G.R.L. Al-Awsi. 2018. "Expression of CDKN2A (P16/Ink4a) among Colorectal Cancer Patients: A Cohort Study." *Journal of Pharmaceutical Sciences and Research* 10 (5).
- Ali, N.; Keshavarz, H.; Rezaian, M.; Khorramizadeh, M. R.; Kazemi, B.; Fazaeli, A.; & Darde, M. (2005). Molecular characterisation of *Toxoplasma gondii* from bird hosts. *Iranian. J. Publ. Health.*, 34(3): 27-30.
- Al-Jubouri, Saadia Aziz. (2010). Internal and external parasitic infections in domestic chickens. (Linnaeus, 1958) *Gallus gallus domesticus* in the city of Diwaniya. Master Thesis. The University of Qadisiyah. Faculty of Education. 118 pages.
- Alkhaled, M. J. A. (2012). Serological and Molecular study of Toxoplasmosis in Chickens and Ducks in some regions of middle Euphrates. *Uni. Bagh dad.Vet. Med.*135.
- Al-Ramahi, H. J. (2011). Seroprevalence Study of *Toxoplasma* in Free-Ranging Chiken in Mid. Uni. Babylon. *Vet. Med.* .11.
- Amin, D.; Gholam Reza, H.; Koorosh, S.; & Mohammad, M. (2012). Clinical Serological and histopathological signs of Toxoplasmosis in broiler chicken (*Gallus domesticus*) After experimental infection. *Comp. Clin.Pathol.*, 21: 1379-1382.
- Bancroft, J. D.& Stevens, M. (1982). Theory and Practice of Histological Teaching 2<sup>nd</sup>ed. Charchill, Livingstone. NewYourk. 662.

- Burney, D. P.; Lappin, M. R.; Spiker, M. (1999). Detection of *Toxoplasma gondii* Parasitemia in Experimentally Inoculated Cats. *J. Parasitol.*, 65(5):47-951.
- Dakhil, Mohamed Habib. (2012). Molecular and immunological study of congenital *Toxoplasma gondii* in wild and domestic pigeons and domestic chickens. Master Thesis. The University of Qadisiyah. Faculty of Education.
- Dubey, J. P. & Shen, S. K. (2006). Characterisation of *Toxoplasma gondii* in free-range chickens from Chile, South America. *Vet. Parasitol.*, 140:76-82.
- Dubey, J. P.; Edelhofer, R.; Marcet, P.; Vianna, M. C.; Kwok, O. C. & Lehmann, T. (2005a). Genetic and biologic characteristics of *Toxoplasma gondii* infections in free-range chickens from Austria. *Vet. Parasitol.*, 133: 299- 306.
- Dubey, J. P.; Weijel, R. M.; Siegel, A. M.; Thulliez, P.; Kitron, U. D.; Mitchell, M. A.; Mannelli, A. M.; Mateus-Pinilla, N. E.; Shen, S. K.; Kwok, O. C. H.; Todd, K. S. (1995b). Sources and Reservoirs of *Toxoplasma gondii* infection on 47 swine, Farms in Illinois. *J. Parasitol.*, 81(5):723-729.
- Dysfunction in Cats Programmatically Cited. *Iraqi Journal of Veterinary Sciences*. College of Veterinary Medicine. University of Mosul
- El-Massry, A.; Mahdy, O. A.; El-Ghaysh, A. & Dubey, J.P. (2000). Prevalence of *Toxoplasma gondii* antibodies in sera of turkeys, chickens, and ducks from Egypt. *J. Parasitol.*, 86 627-628.
- Foulon, W.; Villena, I.; & Stray-Pedersen, B. (1999). Treatment of toxoplasmosis during pregnancy: a multinuclear study of the impact on fetal transmission and children sequelae at age 1 year. *Am. J. Obstet. Gynecol.*, 180: 410- 415.
- Gyton & Hull. (1995). *Textbook of Medical Physiology*. 9/ E.W.B. Saunders Company.
- Hassan, Hussain Fadel (2016). The parasitic period. The first edition. Fuzuli edition, Kirkuk.
- Hasson, K. F. (2004). Sero-epidemiological study of toxoplasmosis among pregnant women with gynaecological and obstetrical problems in Najaf city. M. Sc.thesis, College of Medic. Uni. Kufa.
- Ho-Yen, D.O. (1992). Clinical features. In D. O. Ho-Yen, and A. W. L. Joss (ed.), *Human toxoplasmosis*. Oxford Medical Publications, Oxford, United Kingdom, 56-78.
- Khurana, S.; Bagga, R.; Aggarwal, A.; Lyngdoh, V. ; Shivapriya, diddi, K.; Malla, N. (2010). Serological screening for antenated *Toxoplasma* infection in India. *Vol. 28(2): 143-146*.
- Liesenfeld, O. (2002). Oral infection of C57BL/6 mice with *Toxoplasma gondii*: A new module of inflammatory. *J. Infect Dis.* 1585-1596.
- Mary, E. K. (1998). Pulsed-Field Gel Electrophoresis. *Molecular Bacteriology*. Central public health laboratory, London, UK., 3: 33-50.
- Niazi, A. D. (2001). Statistical analysis in medical research. Uni. The Nahrei Republic of Iraq. 148.
- Salim, M. A. and Abed S.A, 2017. Avifauna Diversity of Bahr Al-Najaf Wetlands and the Surrounding Areas, Iraq. *Jordan Journal of Biological Sciences*. Vol. 10 (3), Pages 167 – 176.
- Sambrook, J.; Fritsch, E. F. & Maniatis, T. (1989). *Molecular cloning: a laboratory manual*. 2nd.Ed. Gold spring harbor. New York. The USA. (Cited by ALKhled, M. J. A. (2012).
- Shamran, A. R, Shaker, Z. H, Al-Awsi, G. R. L, Khamis, A. S, Tolaifeh, Z. A. and Jameel, Z. I, 2018. RAPD-PCR IS A GOOD DNA FINGERPRINTING TECHNIQUE TO DETECT PHYLOGENETIC RELATIONSHIPS AMONG STAPHYLOCOCCUS AUREUS ISOLATED FROM DIFFERENT SOURCES IN HILLA CITY, IRAQ. *Biochemical and Cellular Achieves*. Vol. 18, Supplement 1, pp. 1157-1161.
- Simpson, M. (2002). *Toxoplasma gondii*-Life Cycle, Morphology, Pathogenesis, the attachment to and Entry into the host cell. (Internet).
- Sreekumar, C.; Graham, D. H.; Dahl, E.; Lehmann, T.; Raman, M.; Bhalerao, D. P.; Vianna, M. C. B. & Dubey, J. P. (2003). Genotyping of *Toxoplasma gondii* isolates from chickens from India. *Vet. Parasitol.*, 118: 187-194.
- Sturkie, P. D. (1965). *Avian physiology*. Cornell. Uni-Press: 75.
- Tali, Ahlam Fathi Mahmoud, Abbas, Nashwan Adnan, Mohammed, Ahed Hassan, Zarzis, Bashar Mohammed, Hussein, Yousry Yahya (2005). Detection of antibodies to *T. gondii* cones in the meat breeds in Nineveh province. *Journal of medicine Duhok*.
- Yan, C.; Yue, C. L.; Yuan, Z. G.; He, Y.; Yin, C. C.; Lin, R. Q.; Dubey, J. P. & Hu, X. Q. (2009). *Toxoplasma gondii* infection in domestic ducks, free-range and caged chickens in southern China. *Vet. Parasitol.*, 165(3-4): 337- 40.