



## Portal vein thrombosis post-splenectomy in thalassemia major patients

Kussay M. Abbas Zwain<sup>1</sup>, Samer M. Mohamed Al-Hakkak\*<sup>2</sup>, Alaa A. Al-Wadees<sup>2</sup>,  
Zainab Mahdi Majeed<sup>3</sup>

<sup>1</sup>Department of Surgery, Faculty of Medicine, Kufa University, Najaf city, Iraq

<sup>2</sup>Department of Surgery, Faculty of medicine, Jabir Ibn Hayyan Medical University, Najaf city, Iraq

<sup>3</sup>Department of surgery, AL-Sader teaching Hospital, Ministry of Health, Najaf city, Iraq



### Article History:

Received on: 17.06.2019  
Revised on: 12.09.2019  
Accepted on: 18.09.2019

### Keywords:

portal vein thrombosis (PVT),  
beta-thalassemia,  
splenectomy,  
complication

### ABSTRACT

$\beta$ -thalassemia major is a chronic, inherited hematological disease that leads to chronic anemia in the affected children. One of the options of treatment in such patients was splenectomy; however, it is not without risk of many complications; one of them is the thrombotic events. A prospective study of 55 patients with  $\beta$ -thalassemia inscribes in this study. 14 patients (25.5%) had a normal thrombocyte count and 41 patients (74.5%) have an abnormally high thrombocytes count which was significantly associated with PVT (P. Value <0.001), Regarding the WBC count, it extended between 4000 to more than 30,000, in both genders with non-statistically significant differences between both genders, (P>0.05). Regarding the serum ferritin, the mean level was  $2908.5 \pm 1024.3$  ng/ml. In males, the mean S. Ferritin was relatively higher than that of females,  $3167.6 \pm 1841.3$  mg/dl, and  $2573.8 \pm 1150.6$  ng/ml. The weight of the spleen was up to 1500 grams in 25 (80.6%) of males and 20 (83.3%) of females while it was more than 1500 grams in the remaining and females and males, without a significant difference statistically in the spleen weight of, (P>0.05). The most frequent presenting symptom was abdominal pain. It was founded in 46 patients (83.6%), followed by fever in 76.4%, diarrhea in 58.2%, and Nausea and vomiting in 31 (56.4%). 3 patients out of the 55 (5.5%) developed portal vein thrombosis in their follow up period. Post splenectomy PVT in thalassemia the patient is relatively frequent (5.5%) complication that require a high degree of doubt for diagnosis early, especially in patients with postoperative pain of the abdomen within 2 months after surgery, Female gender, Large spleen and postoperative increase number of platelets are risk factors for PVT so one can initiate surveillance by Doppler ultrasound post-operatively and start antiplatelet prophylactic therapy immediately for such patients.

### \*Corresponding Author

Name: Samer M. Mohamed Al-Hakkak  
Phone: +9647801003495  
Email: sammerhakak1971@yahoo.com

ISSN: 0975-7538

DOI: <https://doi.org/10.26452/ijrps.v10i4.1645>

Production and Hosted by

Pharmascope.org  
© 2019 | All rights reserved.

### INTRODUCTION

The commonest one genetic diseases in men are thalassemia. They take place at a high gene frequency through the Mediterranean people, Indian subcontinent, Middle East, Myanmar, in a line extending from southern China through Thailand and the Malay Peninsula into the island peoples of the Pacific. It is furthermore commonly seen in states in which there has been emigration from this high-frequency population. (Weatherall, 2010). It is an autosomal recessive trait in the chromosome (number eleven)

is affected. It involves the building of the Beta globin chain of hemoglobin, which is either absent or decreased, leading to the shape of red blood cell abnormality. When single beta-globin chain genes are abnormal and other normal, it is called thalassemia minor. If disorder founds later in life and both the genes are affected, it is called thalassemia intermedia. If both the genes are affected and disorder is appearing in life early, it is called a thalassemia major, which is a more attracter disease. (Kliegman, 2016). RBCs with abnormal shaped are rapidly damaged by the reticuloendothelial system, especially in spleen leading to microcytic hypochromic anemia, splenic enlargement, with an overload of iron. Splenomegaly is due to both extra-medullary hematopoiesis and squeezing of abnormal shape RBC's. The patient evolves abdominal prominence and pallor in early life due to splenic enlargement. Other clinical features related to the iron deposition lead to bossing of the skull bone, overgrowth of maxilla bone, cardiomyopathy, and pigmentation of the skin. (Kliegman, 2016). Endocrine glands, like the pancreas, and pituitary may also be affected in iron deposition (Midiri *et al.*, 1999; Brewer *et al.*, 2009). The disease is diagnosed by serum electrophoresis and the peripheral blood film. (Weatherall, 2010). The patient is treated initially by repeated transfusion of blood and chelation iron therapy. (Brewer *et al.*, 2009) splenic removal should be indicated when,

1. Yearly blood needs more than 1.5 times those of splenectomized patients, render that they are on a similar transfusion schedule, and have no other causes for increased exhaustion. Such causes contain new alloantibodies, infection, and alteration in the hematocrit of the transfused blood units. For patients maintain before transfusion hemoglobin level of about 10 g/dl, this increase in transfusion needs represents consumption of more than 200–220 ml of red cells (assuming hematocrit of transfused cells is 75%)/kg/year (Brewer *et al.*, 2009; Cohen *et al.*, 1980). The overload iron rate should also be taken into account. Patients who preserve good effective chelation therapy regardless of increased blood needs, splenic removal may be non-essential. Patients with increasing iron storage in spite of excellent chelation therapy, a decrease in the rate of transfusion, iron loading by splenic removal may be an important part of the overall management of overload iron.

2. Spleen enlargements are associated with symptoms such as early satiety and pain in the left upper quadrant. Huge splenomegaly leads to possible splenic rupture.

3. Decrease white blood cell count or low platelet number due to hypersplenism causes clinical problems (e.g., recurrent bacterial infection or bleeding).

Splenectomy has its complications, early complications specific to excision of spleen include

1. Haemorrhage consequence from a slipped ligation.

2. Haematemesis due to damage to the gastric mucosa.

3. Postoperative dilatation of stomach which is uncommon

4. Left atelectasis is common, and pleural effusion may be found.

5. Near organs at risk through the operation include the pancreas and stomach

6. The fistula may consequence from damage to the stomach greater curvature during ligation of the short gastric vessels.

7. The pancreas tail damaged lead to pancreatic inflammation, a localized abscess or fistula of the pancreas.

8. Postoperative platelet count may increase and, if the blood platelet count exceeds  $1 \times 10^6/\text{mL}$ , aspirin given prophylactic is recommended. Long-term surveillance programs have confirmed an increased risk of pulmonary embolism and DVT (deep Venous thrombosis). The risk is more in the younger patient, in patients with splenectomy that treated with chemoradiotherapy and in patients who have undergone removal of spleen for thalassemia, sickle cell disease, and autoimmune anemia or decrease platelets count. (Modell, 1977)

9. Overwhelming post-splenectomy infection (OPSI) is a major worry. Guidelines emphasized that most infections after splenic removal could be avoided by measurements that offering patients suitable and timely immunization, prophylactic antibiotics, education about prompt infection treatments. Prophylactic antibiotic's advantage remains controversial. It is thought splenic removal done for children before the age of 5 years should be managed with a daily dose of penicillin to the age of 10 years. In older children, prophylaxis should be continued at least to the age of 16 years, while adult's usage is less well known. If splenic removal is planned electively, consideration to give vaccination versus pneumococcus, meningococcus C (both repeated every 5 years), and H. influenzae type B (Hib) (every 10 years repeated). The last two vaccines are commonly delivered as a combined preparation. The vaccination against Influenza has been recommended to given yearly, as in this setting has

**Table 1: Causes of PVT**

Hypercoagulable States	Malignancies
Myeloproliferative Disorders	HCC
Antiphospholipid Syndrome	Gastric Malignancy
Deficiency of Antithrombin	Cholangiocarcinoma
Mutation of Factor V Leiden	Bladder Cancer
Nephrotic Syndrome	
Oral Contraceptive pill	
Deficiency of protein C, S	
PNH	
Sickle Cell disease	
Infections	Others
Appendicitis	Inflammatory disease
Cholangitis	Inflammation of Pancreas
Diverticulitis	Choledochal Cyst
Umbilical vein infection	Catheterization of the umbilical vein
	Transplantation of liver
	TIPS
	Hepatic Vein Chemoembolization
Impaired Flow of the Portal Vein	
Cirrhosis	
HCC	
Budd-Chiari Syndrome	

**Table 2: Age and gender distribution of the studied group**

Age (year)	Male		Female		Total %	
	No.	%	No.	%		
5 - 9	1	3.2	1	4.2	2	3.6%
10 - 19	17	54.8	15	62.5	32	58.2%
20 - 29	10	32.3	5	20.8	15	27.3%
≥ 30	3	9.7	3	12.5	6	10.9%
Total	31	56.4	24	43.6	55	100%

**Table 3: Platelets count of the studied group**

Platelets count (x 1000)	Male		Female		Total %		P. value
	No.	%	No.	%			
Normal (150 - 450)	7	22.6	7	29.2	14	25.5%	0.83
451 - 1000	19	61.3	13	54.2	32	58.2%	
> 1000	5	16.1	4	16.7	9	16.3%	
Total	31	56.4	24	43.6	55	100%	

not been assessed adequately. (Modell, 1977)

### Types of surgery in thalassemia

Splenectomy was done by the two most common surgical techniques, the laparoscopic and open methods. The laparoscopic technique needs a longer surgical time and may not be logical for patients with huge spleens, but the patient recovery is shorter, and there is virtual scar less surgery.

Many surgeons now have good experience with these techniques.

In some centers, partial splenic removal is used to maintain some of the immune functions of the spleen while decreasing the degree of hypersplenism (Williams and ., 2018). The long-term success of these methods is yet undergoing assessment. In particular, the likeliness of splenic re-growth and

**Table 4: White blood cells count of the studied group**

WBC count (x 1000/ml)	Male		Female		Total 100%		P. value
	No.	%	No.	%			
4 - 10	2	6.5	3	12.5	5	9.1 %	0.49
11 - 20	15	48.4	8	33.3	23	41.8%	
21 - 30	4	12.9	6	25.0	10	18.2%	
> 30	10	32.3	7	29.2	17	30.9%	
Total	31	56.4	24	43.6	55	100%	
Mean $\pm$ SD	27.1 $\pm$ 8.5		23.6 $\pm$ 4.2				0.28
SD: standard deviation							

**Table 5: Serum Ferritin of the studied group**

S. Ferritin (ng/mL)	Male		Female		Total	P. value	
	No.	%	No.	%			
300 - 1000	10	32.2	5	20.8	15(27.3%)	0.23	
1000 - 5000	15	48.4	17	70.8	32(58.2%)		
> 5000	6	19.4	2	8.4	8 (14.5%)		
Total	31	56.4	24	43.6	55 (100%)		
Mean $\pm$ SD*	3167.6 $\pm$ 1841.3		2573.8 $\pm$ 1150.6		0.37		
*SD: standard deviation							

**Table 6: Splenic weight of the studied group**

Splenic weight (gm)	Male		Female		Total %	
	No.	%	No.	%		
200 - 1500	25	80.6	20	83.3	45	81.8%
> 1500	6	19.4	4	16.7	10	18.2%
Total	31	56.4	24	43.6	55	100%

(P&gt;0.05)

**Table 7: Presenting symptoms of the studied group**

Symptom	No.	%
Abdominal Pain	46	83.6
Fever	42	76.4
Diarrhea	32	58.2
Nausea and Vomiting	31	56.4
GIT bleeding	6	10.9
Ascites	3	5.5

**Table 8: Incidence of PVT according to gender**

Portal vein Thrombosis	PVT		No PVT		Total
	No.	%	No.	%	
Male	1	3.2%	30	96.8%	45
Female	2	8.3%	22	91.7%	10
Total	3	5.5	52	94.5	55
Fisher's Exact test, P. value = 0.58					

**Table 9: Comparison of Age, hematological parameters and spleen weight according to PVT**

	PVT		No PVT		P.value
	Mean	SD	Mean	SD	
Age	18.9	7.5	20.3	8.4	0.55
S. Ferritin	1190.00	546.2	3007.63	2455.4	0.20
WBC (x 10 <sup>3</sup> )	17.77	4.2	24.3	19.9	0.88
Platelet (x 10 <sup>3</sup> )	1207.00	194.0	609.0	272.0	0.001
Spleen weight (gm)	2056.67	150.1	1008.1	331.8	<0.001

the volume of splenic tissue required to preserve immune function are two questions outstanding. Any splenectomy should include a careful search for access spleens.

Decrease of tissue of the splenic by embolization is a less invasive method to hypersplenism than complete or partial surgical splenic removal (Montalembert *et al.*, 1990). But, this method has not got wide acceptance and may be complicated by pain, fever, and the possible requirement for a subsequent total splenic removal. Embolization does not allow a search for accessory spleens. An evaluation for gallbladder stones should be done before surgery, particularly if the patient has had symptoms suggesting of biliary tract disease. In some cases, positive findings will lead to gallbladder removal at the same time with splenic surgery. Appendix removal at the time of splenic removal may prevent later problems in distinguishing *Yersinia enterocolitica* infection from inflammation of the appendix. Splenic removal also supplies a perfect chance for biopsy of the liver to assess the histology of the liver and concentration of iron. (Pringle *et al.*, 1982)

### Portal vein thrombosis(PVT)

Portal vein thrombosis (PVT) defined to the occlusion in the main trunk of the portal vein. The portal vein accounts for seventy-five percent of the blood nourishment of the liver. It is 8mm wide, valveless conduit arising from the confluence of the splenic vein and superior mesenteric vein posterior to the neck of the pancreas. The vascular disease is important because of its significant morbidity and mortality, which can happen without timely diagnosis or disease-specific management, or even with an appropriate workup. (Cappellini *et al.*, 2008). PVT can be a dangerous disease and fatal complication of splenic removal if not discovered early and treated properly. The early record of this complication characterized it as an uncommon complication accompanied by great morbidity and mortality (Deleve *et al.*, 2009). It is becoming obvious that

PVT occurs more often than previously register due to advance improvement in quality of radiographic techniques (Ellison and Fabri, 1983). Also, several groups (Hassn *et al.*, 2000; Condat *et al.*, 2000) recently reported effective management of PVT with total resolution of a clot in some post-splenectomy patients. Although some advance has been made in grasping the nature of post-splenectomy PVT, many remarkable clinical questions stay not answered. Many factors have been implicated in the causes of PVT, but the subset of patients at the highest risk has not been identified. Also, given the concern that patients may be getting high risk for bleeding after splenic removal, the role of postoperative anticoagulation prophylactic needs explanation.

### Etiology of PVT

The etiology of PVT is quite different. Both local and systemic factors have present to play a part in the creation of s portal vein thrombus. There are three variables of Virchow's triad— endothelial trauma, blood flow stasis, and increase coagulability play a function in PVT. Table 1 shows,

Thrombophilic disorders form a significant cause of PVT, especially in cases previously believed as idiopathic. Like, myeloproliferative disorders (MPD) are the most predominant; 20% thrombosis of the portal vein cases may have an underlying MPD. Considerably, they are the first display of myeloproliferative disorder. (Rhee *et al.*, 1994; Baxter *et al.*, 2005; James *et al.*, 2005; Kralovics *et al.*, 2005; Levine *et al.*, 2005). From the hemostatic standpoint, the patient with thalassemia is characterized by increased coagulability and a high risk of venous and/or arterial thromboembolism. However, not all of the thalassemia patients exist with the same risk, and the higher risk identification is not possible on the grounds of the measurements of the individual components of the hemostatic system, nor the ground of such universal conventional coagulation tests as the activated partial thromboplastin times and prothrombin time (PT, APTT). Non successful

of these tests to recognize thalassemic hypercoagulability state might be due to the absence of red blood cells and thrombocytes, which may play a key role in the mechanics responsible for thrombosis in this setting ([Patel et al., 2006](#); [Michaeli et al., 1992a](#); [Sumiyoshi et al., 1992a](#))

### Presentation of PVT

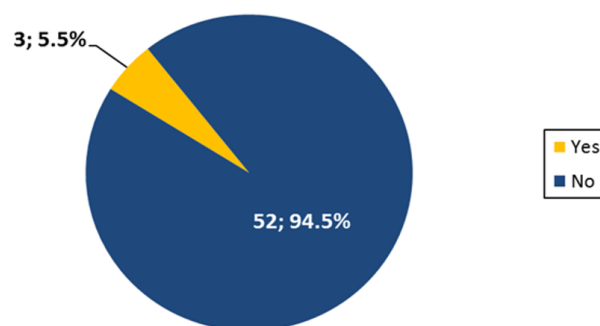
Clinically may be acute or chronic. Although no sharp time frame exists, to identify acute from chronic PVT, it usually looks acute if the symptoms appeared less than sixty days before hospital assessment. ([Gillis et al., 1999b](#)). This may not always contract as patients with chronic PVT may present firstly with upper gastrointestinal bleeding. An easy way to differentiate acute from chronic PVT is the absence or insignificant Porto-portal collaterals on imaging and no proof of portal hypertension, including splenic enlargement and varices of the esophagus.

### Acute Portal Vein Thrombosis

In acute PVT, there is an immediate formation of thrombosis within the portal vein that drives to partial or total occlusion of the portal vein. Acute PVT in non-cirrhotic non-malignant PVT usually exists with fever, the pain of the abdomen, and small volume ascites. ([Eldor and Rachmilewitz, 2002](#)) Splenic enlargements are seen in 37% of patients, and 40% of which have an underlying MPD disorder. In the remaining 63% of patients without splenic enlargement, MPD is founded in only 5% of patients. 26 involvement of superior mesenteric vein and the arches of the mesenteric venous plexuses may lead to bowel infarction, intestinal ischaemia, and ileus. Patients may then exist with fever, rebound tenderness, hematochezia, and ascites. Bowel infarction is an important leading cause of death in patients with thrombosis of the portal venous system. ([Malkowski et al., 2003](#)). Partial occlusion of the portal vein may be associated with lesser symptoms. Development of acute ascites, though rare, may also be seen, which is usually mild and transient due to bowel venous congestion. The natural history of an acute attack of PVT is usually undefined and modified by medical management.

### Chronic Portal Vein Thrombosis

Patients with chronic PVT exist with portal hypertension-related complications like well-tolerated variceal bleeding, anemia, splenic enlargement plus decrease platelets count, or maybe without symptoms which discovered incidentally following an imaging method. The children most commonly presented with recurrent upper gastrointestinal bleeding. ([Plessier et al., 2010](#);



**Figure 1: Incidence of PVT**

[Condat et al., 2000](#)). Usually, bleeding happens in the 1st or 2nd decade of life. The bleeding is well tolerated due to the underlying normal function of the liver. Ascites is seen transiently in one-fifth of children following the episode of bleeding. ([Poddar et al., 2008](#)) About 10% of children exist with isolated splenic enlargement. ([Valla et al., 2002](#)) Splenic enlargements are almost global and maybe symptomatic with left upper quadrant abdominal pain (due to huge splenic enlargement) or as pain (due to splenic infarction) or sometimes as symptomatic hypersplenism. Chronic PVT in adults exist with recurrent upper gastrointestinal bleeding like children. Other rare clinical presentations include cholangitis, obstructive jaundice, and even choledocholithiasis late in the natural course of the disease due to portal hypertensive biliopathy or pseudosclerosing cholangitis. ([Rangari et al., 2003](#); [Arora et al., 1998](#); [Dilawari and Chawla, 1992](#); [Khuroo et al., 1993](#); [Dhiman et al., 1999](#); [Condat, 2003](#))

### Diagnosis of PVT

#### Liver Function

The function of the liver is normal or near-normal except if PVT occurs in a patient with cirrhosis. Levels of prothrombin and other factors of coagulation may be low, while D dimer is usually high. ([Malkan et al., 1999](#); [Sezgin et al., 2003](#)) Alkaline phosphatase may be raised in patients with portal hypertensive biliopathy. Liver show atrophy, grossly normal, and regenerative nodular hyperplasia in PVT, related to apoptosis and compensatory arterial vasodilation in chronic PVT. ([Condat and Valla, 2006](#); [Kocher and ., 2005](#)). Liver function disruption may be seen in extrahepatic portal vein obstruction in the form of ascites, prolongation of prothrombin time, and low serum level of albumin in patients with prolonged hypertension. ([Poddar et al., 2008](#))

#### Ultrasound

The investigation of preference is ultrasound. It displays solid hypoechoic or isoechoic material within

the portal vein either, filling the lumen completely or partially. (Vilgrain *et al.*, 2006) it is the cheapest technique, but specificity and sensitivity are influenced by patient variability and experience of the radiologist. (Vilgrain *et al.*, 2006; Bilodeau *et al.*, 1999).

The specificity and sensitivity of ultrasound for detecting portal vein thrombosis range from 80 to 100 % with an accuracy of 88–98%. A manifestation of a portal cavernoma (multiple tortuous small vessels replacing the portal vein) is revealing of chronic PVT and is usually associated with splenic enlargement and collaterals concerning the portal venous system. Doppler ultrasonography and Pulsed Wave ultrasonography show the absence or decrease portal vein flow. The diagnostic sensitivity and specificity for Doppler Ultrasound in finding portal vein thrombosis vary from 66% to 100%. (Gansbeke *et al.*, 1985; Wang *et al.*, 2005) Contrast-enhanced ultrasound is another modality that is superior to ultrasound in the show the existence or absence of flow and is more reliable in patients with very low portal vein velocity. Endoscopic ultrasound has also been announced to be sensitive (81%) and specific (93%) testing to diagnose PVT. (Tessler *et al.*, 1991; Parvey *et al.*, 1994; Lai and Brugge, 2004) Ultrasound show gallbladder varies on about 12–30% of adults with chronic PVT. (P Palazzo L and ., 2000)

### Computed Tomography and Magnetic Resonance Imaging

CT and MRI provide more precise details such as an extension of the thrombus, proof of bowel ischemia, and status of neighbor organs. Without contrast-enhanced CT, portal vein thrombus is generally seen to be isodense to adjacent soft tissue but may be hyperdense if it occurred within a month. (Umphress *et al.*, 2004) Following IV administration of iodinated contrast on CT, a bland thrombus is seen as a low density, non-enhancing defect within portal veins, while a tumor thrombus enhances following administration of contrast. Furthermore, dynamic CT shows a filling defect partially or obstructing the vessel lumen with rim enhancement of the wall of the vessel. (Chawla *et al.*, 1995) Sure other features of malignant portal vein occlusion include disarrangement of the walls of the vessel and intra thrombus arterial neovascularization and expansive effect (portal vein enlargement due to the mass forming thrombus). MR portography is better than Doppler ultrasound in discovering partial thrombosis and obstruction of the main portal venous trunk. It also detects portosplenic collaterals and portal vessels more sufficient that cannot be seen in color Doppler. (Par-

vey *et al.*, 1994). Currently used therapeutic methods have an essential lengthy life expectancy in patients with thalassemia (Lee *et al.*, 2008). A result of this is the manifestation of new complications. Venous thromboembolic conditions, such as pulmonary embolism, DVT, and PVT, have been observed (Cakmak *et al.*, 2008; Olivieri and Brittenham, 1997; Sonakul *et al.*, 1990; Michaeli *et al.*, 1992b; Sumiyoshi *et al.*, 1992b). However, there are relatively small data on the total frequency of these complications. So this study aims to discover the incidence of such complications.

### Aim of Study

- 1- To identify the incidence of PVT in beta-thalassemia patients after splenic removal
- 2- To detect any correlation of PVT and the blood parameters after splenectomy, as well as any gender prevalence as a risk factor.

### PATIENTS AND METHODS

A descriptive prospective study of 55 patients with  $\beta$ -thalassemia conducted from the first of October 2015 for the first of September 2018, the selected patients underwent splenectomy in Al-Sader medical city / surgical department and followed up in Al-Zahra thalassemia unit in Najaf governorate. The selection criteria of splenectomy were:

Patients with blood transfusion requiring no more than 250 ml/kg/year.

Hugely enlarged spleen with dragging pain or respiratory embarrassment.

Complications, such as pancytopenia (hypersplenism).

In this study, all children were assessed by review of their medical records, assessment of medical history, and clinical examinations. In addition to complete blood count, a test of liver function, and serum level of ferritin were performed as well as weighing the spleen postoperatively; meticulous care was taken to ensure removal of splenunculi during surgery and preoperative anti-pneumococcal vaccine were given to all patients. All patients underwent open splenectomy. Follow up is performed in Al-Zahra/ thalassemia unit for 6 months by monthly CBC, serum ferritin, liver function test. Coloured Doppler ultrasound was done for any patient with any symptom/s suggestive of being due to PVT, mostly abdominal pain. PVT was reported as (portal vein is distended filled with hypoechoic thrombus and shows no flow) by Colored Doppler ultrasound. The data were resolved using the Fisher exact test. A P value of  $\leq 0.05$  was considered significant.

## RESULTS AND DISCUSSION

There was 55 patients record in this work with a mean age of  $19.5 \pm 7.3$  (range: 7 – 38) years. They were 31 males (56.4%) and 24 females (43.6%). (Table 2).

### Platelet and White blood cells count

As it is shown in table 3, among males, 7 (22.6%) had a normal level of platelet count, 19 (61.3%) had a platelet count of 451 – 1000, and 5 males (16.1%) had a platelet count of more than 1000 /ml. Among females, 7 (29.2%) had normal, 13 (54.2%) had 451 – 1000, and 4 (16.7%) had a platelet count of more than 1000/ml. No statistically significant difference had been found in platelet count between both genders ( $P>0.05$ ). Regarding the WBC count Table 4, it ranged between 4000 to more than 30,000, in both genders with no statistically significant differences between both genders, ( $P>0.05$ ), however, the majority (83.6%) of male and female patients had a WBC count of more than 10,000 cells/ml.

### Serum Ferritin

Regarding the serum ferritin Table 5, the mean level was  $2908.5 \pm 1024.3$  ng/ml. In males, the mean S. ferritin was relatively higher than that of females,  $3167.6 \pm 1841.3$  mg/dl, and  $2573.8 \pm 1150.6$  ng/mL, with no statistically significant difference between both genders, ( $P>0.05$ ). On the other hand, the distribution of S. ferritin across both genders, revealed that 32.3% of males and 20.8% of females had S. ferritin of less than 1000 ng/mL, 15 males (48.4%) and 17 females (70.8%) had a level of 1000 – 5000 and 6 males (19.4%) and 2 females (8.3%) had a level of more than 5000 ng/mL, and the difference did not reach the statistical significance, ( $P>0.05$ ).

### Splenic weight

The weight of the spleen was up to 1500 grams in 25 (80.6%) of males and 20 (83.3 %) of females while it was more than 1500 grams in the remaining males and females, with no statistically significant difference in the weight of spleen, ( $P>0.05$ ), (Table 6).

### Presenting symptoms

In general, among the total 55 patients, abdominal pain was the more frequent presenting symptom, it was reported in 46 patients (83.6%), followed by fever in 76.4%, diarrhea in 58.2% and Nausea & vomiting in 31 (56.4%), other symptoms; GIT bleeding and ascites were less frequent accounted for 10.9% and 5.5%, respectively. It is worth mentioning that the majority of patients had more than one presenting symptom at the same time (Table 7).

### Incidence of Portal vein thrombosis (PVT):

Three patients out of 55 (5.5%) developed Portal vein thrombosis during their follow up period (Figure 1). They were one/31 male (3.2%) and two /24 females (8.3%). The incidence was higher in females compared to males with a relative risk of 2.58 which indicated that females were about 2.6 folds more likely to have PVT, however, due to the low number of patients with PVT, the difference did not scope the statistical significance, ( $P>0.05$ ), (Table 8). The time of presentation post-splenectomy was at 21, 26, 35 days.

Furthermore, a comparison was made between PVT patients and those with no PVT in age, hematological and splenic weight; results of this comparison are shown in (Table 8), were no statistically significant differences had been found between both subgroups in age, S. ferritin levels or the WBC counts, in all comparison ( $P>0.05$ ). Platelet count was significantly higher in PVT than non-PVT subgroups, it almost doubled,  $1207.0 \pm 194.0$  vs.  $609.0 \pm 272.0$ , respectively, (P. value = 0.001). Spleen weight was significantly larger in PVT than non-PVT subgroup,  $2056.7 \pm 150.1$  grams and  $1008.1 \pm 331.8$  grams, respectively, (P. value < 0.001), (Table 9)

We studied 55 patients with  $\beta$ - thalassemia who did splenectomy for different indications for any evidence of PVT for six months in Al-Najaf thalassemia center with male predominance, 31 males and 24 females (M: F 1.29:1) which is the same result of other studies. (Kliegman, 2016; Midiri *et al.*, 1999). In this study the age predominance of splenectomy was between 10-19 years (average 19.5 years, 32 patients, 58.2%) which is comparable to comparative study between 2 people of patients from (Kurds) Iraq and Arabia Saudi, both of whom subjected to splenic removal for thalassemia, The average age of the Saudi patients who subjected to splenic removal was 17 years, while the Iraqi's who underwent total splenic excision had an average age of 14.5 years (Sheikha *et al.*, 2007) while in a study done by Ravi Shah the average age of splenic excision was  $8.0 \pm 2.4$  years (5–15 year). (Shah *et al.*, 2014). Regarding platelet count post-splenectomy, 74.5% of our patients had thrombocytosis above  $450 \text{ k}/\mu\text{L}$  starting 24-hour post-surgery while 25.5% had a normal range, while in a study done by (Ammar, 2014) the range was  $644.700 \pm 299.4 \text{ k}/\mu\text{L}$  in all splenectomized patients. Thrombosis following splenectomy had been reported in the literature (Mohren *et al.*, 2004; Boyle *et al.*, 2013; Harris and Marcaccio, 2005). Splenic removal leads to instant 21 reactive high platelets counts and an increase in circulating microparticles, with an increased risk of subsequent venous thromboembolism particularly within the splenoportal system (Rodeghiero and Ruggeri,



2012; Ho *et al.*, 2012; Kashuk *et al.*, 2010; Frey *et al.*, 2014; Wang *et al.*, 2014)

Regarding s. Ferritin, our study shows that all our patients had abnormally high levels of serum ferritin, 72.6% had levels above 1000 ng/ml, and 14.4% had a very high level of s. Ferritin > 5000 ng/ml in spite of using desferrioxamine mesylate (Desferal®) for excess chelating iron regularly. In a study done by (Shah *et al.*, 2014) (41.5 %) of patients were with serum ferritin level > 500 ng/ml, (55.8 %) of patients with level of serum ferritin less than 250 ng/ml (normal range) and 24.6% of patients with serum level of ferritin less than 70 ng/ml this difference in both studies attributed to repeated blood transfusion in our patients in the thalassemia center. Another study was done by (Ammar, 2014) shows serum ferritin average level of  $2893.2 \pm 1409.0$  ng/ml. Splenic removal has been informing to effect the ferritin serum level. A higher level of ferritin in a splenic removal patient as compared to a person with an intact spleen has been described. (Gillis *et al.*, 1999a) The methods for higher iron overload in splenic removal patients are postulated by the reality that the sound spleen may be a tank of spare iron and possibly has an excess spleen effect on iron-free fractions, including non-transferrin-bound iron. (Tavazzi *et al.*, 2001)

Regarding splenic weight, our study shows that 45 patients (81.8%) had splenic weight between 200-1500 gm and massive spleen ( $\geq 1500$  gm) were found in 10 patients (18.2%) with no statistical difference between males and females ( $P > 0.05$ ), while in a study done by (Kolnagou *et al.*, 2013) an increase from about five (615 gm.) to twenty (2030 gm.) times higher than the normal size and weight of the spleen has been observed in twenty (42.5%) patients following splenic removal. Another study was done by (Alexakis *et al.*, 2013) showed that the splenic weight was 871 gm. (587–1042 gm.) Following splenectomy in  $\beta$ -thalassemia patients. All of these results are comparable to our results.

Regarding the incidence of PVT in this study was (5.5%) 3 patients out of the 55, The time of presentation post-splenectomy was at 21, 26, 35 days respectively. The incidence of PVT after splenic removal in a study done by (Winslow *et al.*, 2002) was 8% a rate higher than our study, (Rattner, 1993) reported a happening of a PVT of only 0.7% in a series of 1000 patients, and can't (&apos;t Riet *et al.*, 2000) explain a 2% incidence of this complication while others (Hassn *et al.*, 2000; Chaffanjon and Brichon, 1998; Loring *et al.*, 1998) have explained an incidence of PVT, as find out by routine post-operative imaging of 7-10%, so our results are comparable to

these studies. (Winslow *et al.*, 2002) showed that the symptomatic presentation in patients who develop PVT was at a mean interval of  $11.8 \pm 4.6$  days (range 2-22 days) postoperatively while in our study the range was 21-35 days. A few studies showed that thalassemia per se is susceptible to vein thrombosis, especially portal vein and other abdominal vessels with or without splenectomy. (Panigrahi and Agarwal, 2007; Targarona, 2008; Stamou, 2006; Cadili and Gara, 2008) A study was done by (Hassan *et al.*, 2011) showed that many factors, such as V-Leiden, prothrombin 20201-A, increase platelets count are responsible for PVT.

In this study the incidence of PVT was higher in females compared to males with a relative risk of 2.58 which indicated that females were about 2.6 folds more likely to have PVT, however, due to the low number of patients with PVT, the difference did not scope the statistical significance ( $P > 0.05$ ) while in the study done by (Winslow *et al.*, 2002) 77 male incidence were 4/37 (10.8%) and female incidence were 4/56 (7.1%) i.e. males have 1.5 fold more risk of developing PVT which does not go with this study. In this study age, serum ferritin, WBC count has no statically significant relation in patients with PVT in spite of their high levels (0.55, 0.20, and 0.88 respectively) while platelet count and splenic weight had a statically significance correlation in patients with PVT. In the study done by (Winslow *et al.*, 2002), the 2 most important risk factors for PVT post-splenectomy where the underlying haematological disease (myeloproliferative disorders and hemolytic anemia) and splenomegaly. The association between increase platelets count and PVT is unclear because not all patients with PVT had post-splenectomy thrombocytosis and some patients with PVT had a normal or even thrombocytopenia, (Winslow *et al.*, 2002) on the other hand, in this study the association between PVT and thrombocytosis was clear and statistically significant and in fact 74.5% of our patients have abnormally high levels of platelet count. In a study done by (Pignatti *et al.*, 1998) Borgna Pignatti et al., 1988, Female gender, low levels of coagulation inhibitors, thrombocytosis, and huge splenomegaly are predisposing factors for promoting PVT. This result is consistent with ours, where all our patients who developed PVT had a massive spleen >2000 gm. A good explanation is that the pressure on splenic vein by the massive spleen and anatomical factors (long splenic stump) could contribute to this association. In this study, all the patients who developed post-splenectomy PVT received immediate anticoagulation for at least 3 months, and their follow up to indicate the complete resolution of the clot and patency

of the portal system and the mortality rate was zero.

## CONCLUSIONS

Postsplenectomy PVT in the thalassaemic patient is relatively frequently (5.5%) that complication requires a high degree of doubt for early detection and diagnosis.

One should consider the diagnosis of post-splenectomy PVT in any patient who complains of unexplained pain of abdomen, anorexia, and fever within the first 2 months post-surgery.

Female gender, huge spleen, and postoperative thrombocytosis are risk factors for PVT, so one can initiate antiplatelet prophylactic therapy immediately for such patients. Routine postoperative surveillance by Doppler study starting immediately may be of help in detecting early cases as most of these cases are easily treatable by anticoagulation.

## Declarations

Ethical consent has been taken from all patients.

**Research registry:** 5083

**Consent for publication:** Consent has been taken from the institution and the patients.

**Material and data:** The data used and/or resolved during the current study are ready from the corresponding author on need.

**Competing interests:** All authors stat they don't have any conflict of interest.

**Funding:** Authors declare not received any funds from any source.

**Authors' contributions:** <sup>1</sup> Has conceptualized, and designed the study and also the surgeon who performed all open surgery splenectomy, gain interpretation and analysis of data

<sup>2</sup> The corresponding author accepts total responsibility for the study and/or the attitude of the work, had access to the information, and planned the decision to publish, revised the article grammar adjusted ideal content and final agreements of the version to be published

<sup>3</sup> Writing assistance, an assistant surgeon who performed surgery and follow up the patients

<sup>4</sup>Data collected and followed up the patients, drafting the article

## REFERENCES

Alexakis, N., Dardamanis, D., Albanopoulos, K., Ptohis, N., Skalistira, M., Karagiorga, M., Leandros, E. 2013. Incidence, Risk Factors, and Outcome

of Portal Vein Thrombosis After Laparoscopic-Assisted Splenectomy in  $\beta$ -Thalassemia Patients: A Prospective Exploratory Study. *Journal of Laparoendoscopic & Advanced Surgical Techniques*, 23(2):123-128.

Ammar, S. A. 2014. Splenectomy for patients with  $\beta$ -thalassemia major: long-term outcomes. *The Egyptian Journal of Surgery*, 33:232-236.

&apos;t Riet, M. V., Burger, J. W. A., Muiswinkel, J. M. V., Kazemier, G., Schipperus, M. R., Bonjer, H. J. 2000. Diagnosis and treatment of portal vein thrombosis following splenectomy. *British Journal of Surgery*, 87(9):1229-1233.

Arora, N. K., Lodha, R., Gulati, S., Gupta, A. K., Mathur, P., Joshi, M. S., Mitra, D. K. 1998. Portai hypertension in North Indian children. *The Indian Journal of Pediatrics*, 65(4):585-591.

Baxter, E., Scott, L., Campbell, P., East, C., Fourouclas, N., Swanton, S., Curtin, N. 2005. Acquired mutation of the tyrosine kinase JAK2 in human myeloproliferative disorders. *The Lancet*, 365(9464):74230-74236.

Bilodeau, M., Aubry, M. C., Houle, R., Burnes, P. N., Éthier, C. 1999. Evaluation of hepatocyte injury following partial ligation of the left portal vein. *Journal of Hepatology*, 30(1):80005-80006.

Boyle, S., White, R. H., Brunson, A., Wun, T. 2013. Splenectomy and the incidence of venous thromboembolism and sepsis in patients with immune thrombocytopenia. *Blood*, 121(23):4782-4790.

Brewer, C. J., Coates, T. D., Wood, J. C. 2009. Spleen R2 and R2\* in iron-overloaded patients with sickle cell disease and thalassemia major. *Journal of Magnetic Resonance Imaging*, 29(2):357-364.

Cadili, A., Gara, C. 2008. Complications of Splenectomy. *The American Journal of Medicine*, 121(5):371-375.

Cakmak, O., Elmas, N., Tamsel, S., Demirpolat, G., Sever, A., Altunel, E., Killi, R. 2008. Role of contrast-enhanced 3D magnetic resonance portography in evaluating portal venous system compared with color Doppler ultrasonography. *Abdominal Imaging*, 33(1):65-71.

Cappellini, M. D., Cohen, A., Eleftheriou, A., Piga, A., Porter, J., Taher, A. 2008. Guidelines for the Clinical Management of Thalassaemia. NCBI Bookshelf.

Chaffanjon, P. C. J., Brichon, P. Y. 1998. Portal Vein Thrombosis following Splenectomy for Hematologic Disease: Prospective Study with Doppler Color Flow Imaging. *World Journal of Surgery*, 22(10):1082-1086.

Chawla, A., Dewan, R., Sarin, S. 1995. The frequency

- and influence of gallbladder varices on gallbladder function in patients with portal hypertension. *The American Journal of Gastroenterology*, 90:2010–2014.
- Cohen, A., Markenson, A. L., Schwartz, E. 1980. Transfusion requirements and splenectomy in thalassemia major. *The Journal of pediatrics*, 97(1):100–102.
- Condat, B. 2003. Portal cavernoma-associated cholangiopathy: A clinical and MR cholangiography, coupled with MR portography imaging study. *Hepatology*, 37(6):1302–1308.
- Condat, B., Pessione, F., Denninger, M. H., Hillaire, S., Valla, D. 2000. Recent Portal or Mesenteric Venous Thrombosis: Increased Recognition and Frequent Recanalization on Anticoagulant Therapy. *Hepatology*, 32(3):466–470.
- Condat, B., Valla, D. 2006. Nonmalignant portal vein thrombosis in adults. *Nature Clinical Practice Gastroenterology & Hepatology*, 3(9):505–515.
- Deleve, L. D., Valla, D. C., Garcia-Tsao, G. 2009. Vascular disorders of the liver. *Hepatology*, 49(5):1729–1764.
- Dhiman, R. K., Puri, P., Chawla, Y., Minz, M., Bapuraj, J. R., Gupta, S., Suri, S. 1999. Biliary changes in extrahepatic portal venous obstruction: compression by collaterals or ischemic? *Gastrointestinal Endoscopy*, 50(5):80013–80016.
- Dilawari, J. B., Chawla, Y. K. 1992. Pseudosclerosing cholangitis in extrahepatic portal venous obstruction. *Gut*, 33(2):272–276.
- Eldor, A., Rachmilewitz, E. A. 2002. The hypercoagulable state in thalassemia. *Blood*, 99(1):36–43.
- Ellison, E. C., Fabri, P. J. 1983. Complications of Splenectomy: Etiology, Prevention, and Management. *Surgical Clinics of North America*, 63(6):43191–43200.
- Frey, M. K., Alias, S., Winter, M. P., Redwan, B., Stübiger, G., Panzenboeck, A., Lang, I. M. 2014. Splenectomy Is Modifying the Vascular Remodeling of Thrombosis. *Journal of the American Heart Association*, 3(1).
- Gansbeke, D. V., Avni, E., Delcour, C., Engelholm, L., Struyven, J. 1985. Sonographic features of portal vein thrombosis. *American Journal of Roentgenology*, 144(4):749–752.
- Gillis, S., Cappellini, M. D., Goldfarb, A., Ciceri, L., Fiorelli, G., Rachmilewitz, E. A. 1999a. Pulmonary thromboembolism in thalassemia intermedia patients. *Haematologica*, 84:969–969.
- Gillis, S., Cappellini, M. D., Goldfarb, A., Ciceri, L., Fiorelli, G., Rachmilewitz, E. A. 1999b. Pulmonary thromboembolism in thalassemia intermedia patients. *Haematologica*, 84(6):959–60.
- Harris, W., Marcaccio, M. 2005. Incidence of portal vein thrombosis after laparoscopic splenectomy. *Canadian Journal of Surgery*, 48:352–355.
- Hassan, M., Tahereb, G., Tamaddoni, A., Asghar, D., Reza, E., Bijani, A., Mohsen, M. 2011. Correlation of splenectomy with portal vein thrombosis in beta-thalassemia major. *JPMA. The Journal of the Pakistan Medical Association*, (8):760–762.
- Hassn, A., Al-Fallouji, M. A., Ti, O., S. 2000. Portal vein thrombosis following splenectomy. *British Journal of Surgery*, 87:362–373.
- Ho, K. M., Yip, C. B., Duff, O. 2012. Reactive thrombocytosis and risk of subsequent venous thromboembolism: a cohort study. *Journal of Thrombosis and Haemostasis*, 10(9):1768–1774.
- James, C., Ugo, V., Couédic, J. P. L., Staerk, J., Delhommeau, F., Lacout, C., Vainchenker, W. 2005. A unique clonal JAK2 mutation leading to constitutive signalling causes polycythaemia vera. *Nature*, 434(7037):1144–1148.
- Kashuk, J. L., Moore, E. E., Johnson, J. L., Biffl, W. L., Burlew, C. C., Barnett, C., Sauaia, A. 2010. Progressive postinjury thrombocytosis is associated with thromboembolic complications. *Surgery*, 148(4):667–675.
- Khuroo, M. S., Yattoo, G. N., Zargar, S. A., Javid, G., Dar, M. Y., Khan, B. A., Boda, M. I. 1993. Biliary abnormalities associated with extrahepatic portal venous obstruction. *Hepatology*, 17(5):807–813.
- Kliegman, R. M. 2016. *Nelson Textbook of Pediatrics Twentieth Edition*.
- Kocher, G., H. A. 2005. Portal vein thrombosis (PVT): a study of 20 non-cirrhotic cases. *Swiss Medical Weekly*, 135:372–376.
- Kolnagou, A., Michaelides, Y., Kontoghiorghe, C. N., Kontoghiorghe, G. J. 2013. The importance of spleen, spleen iron, and splenectomy for determining total body iron load, ferritokinetics, and iron toxicity in thalassemia major patients. *Toxicology Mechanisms and Methods*, 23(1):34–41.
- Kralovics, R., Passamonti, F., Buser, A. S., Teo, S. S., Tiedt, R., Passweg, J. R., Skoda, R. C. 2005. A Gain-of-Function Mutation of JAK2 in Myeloproliferative Disorders. *New England Journal of Medicine*, 352(17):1779–1790.
- Lai, L., Brugge, W. R. 2004. Endoscopic Ultrasound is a Sensitive and Specific Test to Diagnose Portal Venous System Thrombosis (PVST). *American Journal of Gastroenterology*, 99(1):40–44.
- Lee, H. K., Park, S. J., Yi, B. H., Yeon, E. K., Kim, J. H.,

- Hong, H. S. 2008. Portal vein thrombosis: CT features. *Abdominal Imaging*, 33(1):72-79.
- Levine, R. L., Wadleigh, M., Cools, J., Ebert, B. L., Wernig, G., Huntly, B. J. P., Gilliland, D. G. 2005. Activating mutation in the tyrosine kinase JAK2 in polycythemia vera, essential thrombocythemia, and myeloid metaplasia with myelofibrosis. *Cancer Cell*, 7(4):387-397.
- Loring, L. A., Panicek, D. M., Karpeh, M. S. 1998. Portal System Thrombosis After Splenectomy for Neoplasm or Chronic Hematologic Disorder. *Journal of Computer Assisted Tomography*, 22(6):856-860.
- Malkan, G. H., Bhatia, S. J., Bashir, K., Khemani, R., Abraham, P., Gandhi, M. S., Radhakrishnan, R. 1999. Cholangiopathy associated with portal hypertension: diagnostic evaluation and clinical implications. *Gastrointestinal Endoscopy*, 49(3):70011-70019.
- Malkowski, P., Pawlak, J., Michalowicz, B., Szczerban, J., Wroblewski, T., Leowska, E. 2003. Thrombolytic Treatment of Portal Thrombosis. *Hepato-Gastroenterology*, 50:2098-2100.
- Michaeli, J., Mittelman, M., Grisar, D., Rachmilewitz, E. A. 1992a. Thromboembolic Complications in Beta-Thalassemia major. *Acta Haematologica*, 87(1-2):71-74.
- Michaeli, J., Mittelman, M., Grisar, D., Rachmilewitz, E. A. 1992b. Thromboembolic Complications in Beta-Thalassemia major. *Acta Haematologica*, 87(1-2):71-74.
- Midiri, M., Casto, A. L., Sparacia, G., Angelo, P., Malizia, R., Finazzo, M., Maria, M. D. 1999. MR imaging of pancreatic changes in patients with transfusion-dependent  $\beta$ -thalassemia major. *American Journal of Roentgenology*, 173(1):187-192.
- Modell, B. 1977. Total management of thalassemia major. *Archives of Disease in Childhood*, 52(6):489-500.
- Mohren, M., Markmann, I., Dworschak, U., Franke, A., Maas, C., Mewes, S., Jentsch-Ullrich, K. 2004. Thromboembolic complications after splenectomy for hematologic diseases. *American Journal of Hematology*, 76(2):143-147.
- Montalembert, M. D., Girot, R., Revillon, Y., Jan, D., Adjrad, L., Ardjoun, F. Z., Najean, Y. 1990. Partial splenectomy in homozygous beta-thalassemia. *Archives of Disease in Childhood*, 65(3):304-307.
- Olivieri, N. F., Brittenham, G. M. 1997. Iron-chelating therapy and the treatment of thalassemia. *Blood*, 89:739-761.
- Palazzo L, H., H. C. 2000. Biliary varices on endoscopic ultrasonography: clinical presentation and outcome. *Endoscopy*, 32:520-524.
- Panigrahi, I., Agarwal, S. 2007. Thromboembolic complications in  $\beta$ -thalassemia: Beyond the horizon. *Thrombosis Research*, 120(6):783-789.
- Parvey, H. R., Raval, B., Sandler, C. M. 1994. Portal vein thrombosis: imaging findings. *American Journal of Roentgenology*, 162(1):77-81.
- Patel, R. K., Lea, N. C., Heneghan, M. A., Westwood, N. B., Milojkovic, D., Thanigaikumar, M., Mufti, G. J. 2006. Prevalence of the Activating JAK2 Tyrosine Kinase Mutation V617F in the Budd-Chiari Syndrome. 130:2031-2038.
- Pignatti, C. B., Carnelli, V., Caruso, V., Dore, F., Mattia, D. D., Palma, A. D., Musumeci, S. 1998. Thromboembolic events in beta-thalassemia major: An Italian multicenter study. *Acta Haematologica*.
- Plessier, A., Darwish-Murad, S., Hernandez-Guerra, M., Consigny, Y., Fabris, F., Trebicka, J., Valla, D. 2010. Acute portal vein thrombosis unrelated to cirrhosis: A prospective multicenter follow-up study. *Hepatology*, 51(1):210-218.
- Poddar, U., Thapa, B. R., Rao, K. N., Singh, K. 2008. Etiological spectrum of esophageal varices due to portal hypertension in Indian children: Is it different from the West? *Journal of Gastroenterology and Hepatology*, 23(9):1354-1357.
- Pringle, K. C., Spigos, D. G., Tan, W. S., Politis, C., Pang, E. J., Reyez, H. M., Georgiopolou, P. 1982. Partial splenic embolization in the management of thalassemia major. *Journal of Pediatric Surgery*, 17(6):80461-80463.
- Rangari, M., Gupta, R., Jain, M., Malhotra, V., Sarin, S. K. 2003. Hepatic dysfunction in patients with extrahepatic portal venous obstruction. *Liver International*, 23(6):434-439.
- Rattner, D. W. 1993. Portal Vein Thrombosis After Elective Splenectomy. *Archives of Surgery*, 128(5):565-565.
- Rhee, R. Y., Gloviczki, P., Mendonca, C. T., Petterson, T. M., Serry, R. D., Sarr, M. G., Cherry, K. J. 1994. Mesenteric venous thrombosis: Still a lethal disease in the 1990s. *Journal of Vascular Surgery*, 20(5):688-697.
- Rodeghiero, F., Ruggeri, M. 2012. Short- and long-term risks of splenectomy for benign haematological disorders: should we revisit the indications? *British Journal of Haematology*, 158(1):16-29.
- Sezgin, O., Oğuz, D., Altıntaş, E., Saritaş, Ü., Şahin, B. 2003. Endoscopic Management of Biliary Obstruction Caused by Cavernous Transformation of the Portal Vein. *Gastrointestinal Endoscopy*,

- 58(4):602–608.
- Shah, R., Trehan, A., Das, R., Marwaha, R. K. 2014. Serum Ferritin in Thalassemia Intermedia. *Indian Journal of Hematology and Blood Transfusion*, 30(4):281–285.
- Sheikha, A. K., Salih, Z. T., Kasnazan, K. H., Khoshnaw, M. K., Al-Maliki, T., Al-Azraqi, T. A., Zafer, M. H. 2007. Prevention of overwhelming post-splenectomy infection in thalassemia patients by partial rather than total splenectomy. *Canadian Journal of Surgery*, 50(5):382–386.
- Sonakul, D., Pacharee, P., Laohapand, T., Fucharoen, S., Wasi, P. 1990. Pulmonary artery obstruction in thalassemia. *Southeast Asian Journal of Tropical Medicine and Public Health*, 11:516–523.
- Stamou, K. M. 2006. Prospective Study of the Incidence and Risk Factors of Postsplenectomy Thrombosis of the Portal, Mesenteric, and Splenic Veins. *Archives of Surgery*, 141(7).
- Sumiyoshi, A., Thakerngpol, K., Sonakul, D. 1992a. Pulmonary microthromboemboli in thalassemic cases. *The Southeast Asian Journal of Tropical Medicine and Public Health*, 23(2):29–31. Suppl.
- Sumiyoshi, A., Thakerngpol, K., Sonakul, D. 1992b. Pulmonary microthromboemboli in thalassemic cases. *The Southeast Asian Journal of Tropical Medicine and Public Health*, 23:29–31.
- Targarona, E. M. 2008. Portal Vein Thrombosis After Laparoscopic Splenectomy: The Size of the Risk. *Surgical Innovation*, 15(4):266–270.
- Tavazzi, D., Duca, L., Graziadei, G., Comino, A., Fiorelli, G., Cappellini, M. D. 2001. Membrane-bound iron contributes to oxidative damage of beta-thalassemia intermedia erythrocytes. *British Journal of Haematology*, 112(1):48–50.
- Tessler, F. N., Gehring, B. J., Gomes, A. S., Perrella, R. R., Ragavendra, N., Busuttil, R. W., Grant, E. G. 1991. Diagnosis of portal vein thrombosis: the value of color Doppler imaging. *American Journal of Roentgenology*, 157(2):293–296.
- Umphress, J. L., Pecha, R. E., Urayama, S. 2004. Biliary stricture caused by portal biliopathy: diagnosis by EUS with Doppler US. *Gastrointestinal Endoscopy*, 60(6):2216–2219.
- Valla, D. C., Condat, B., Lebrech, D. 2002. The spectrum of portal vein thrombosis in the West. *Journal of Gastroenterology and Hepatology*, 17(s3):224–227.
- Vilgrain, V., Condat, B., Bureau, C., Hakimé, A., Plessier, A., Cazals-Hatem, D., Valla, D. C. 2006. Atrophy-Hypertrophy Complex in Patients with Cavernous Transformation of the Portal Vein: CT Evaluation. *Radiology*, (1):149–155.
- Wang, J. T., Zhao, H. Y., , L. Y. 2005. Portal vein thrombosis. *Hepatobiliary & Pancreatic Diseases International*, 4:515–518.
- Wang, M., Zhang, M., Li, J., Zhou, J., Wu, Z., Peng, B. 2014. Risk factors of portal vein thrombosis in patients with beta-thalassemia major after splenectomy: laparoscopic versus an open procedure. *Hepato-Gastroenterology*, 61:48–52.
- Weatherall, D. J. 2010. The thalassemias: disorders of globin synthesis. pages 725–725. 9th Editio(48.
- Williams, N. S., , C. P. M. C. A. 2018. *Bailey and Love's short practice of surgery*. Spleen, 27(66):1097–1098.
- Winslow, E. R., Brunt, L. M., Drebin, J. A., Soper, N. J., Klingensmith, M. E. 2002. Portal vein thrombosis after splenectomy. *The American Journal of Surgery*, 184(6):631–635.