



Wound healing activity of chloroform extract of *Coccinia grandis* on excision, incision & dead space wound model in rats

Deepti B^{*1}, Sasidhar K¹, Sadhana G¹, Srinivasa babu P¹, Santhrani Thaakur²

¹Vignan Pharmacy College, Vadlamudi, Guntur. A.P., India

²Padmavathi Mahila University, Tirupathi. A.P., India

ABSTRACT

Coccinia grandis is well known in Traditional system of Indian medicine. It is effective against mouth ulcers, diabetes, liver related disorders, asthma, injuries, pain, constipation etc. The present study was aimed for evaluation of wound healing property of chloroform extract of *Coccinia grandis* on Excision, Incision & Dead space wound models in rats. The results were comparable to standard drug (i.e., Nitrofurazone) & control in terms of wound contraction, period of epithelialisation, tensile strength & hydroxyproline content. The results indicate that chloroform extract exhibit significant wound healing activity when compared to standard & control.

Keywords: *Coccinia grandis*; Nitrofurazone; Tensile strength; Wound contraction.

INTRODUCTION

Wounds are physical injuries that result in an opening or break of the skin. Proper healing of wounds is essential for the restoration of disrupted anatomical continuity and disturbed functional status of the skin (Begum, 2000). Wound Healing is a complex and intricate process initiated in response to an injury that restores the function and integrity of damaged tissue. Healing is characterized by homeostasis, re-epithelialisation, granulation tissue formulation and remodelling of the extracellular matrix (Priya *et al.*, 2002). Initial stages of wound healing involve an acute inflammatory phase followed by synthesis of collagen and other extracellular matrix which are later remodelled to form scar. Wound healing involves continuous cell-cell and cell-matrix interactions that allow the process to proceed in three overlapping phases viz. inflammation (0–3 days), cellular proliferation (3–12 days) and remodelling (3–6 months) (Glyn, 1981; Clark, 1996; Martin, 1996). Healing requires the collaborative efforts of many different tissues and cell lineages (Martin, 1997). It involves platelet aggregation and blood clotting, formation of fibrin, an inflammatory response to injury, alteration in the ground substances, angiogenesis and reepithelialization. Healing is not complete until the disrupted surfaces are firmly knit by collagen (Buffoni *et al.*, 1993). The basic principle of optimal wound healing is to minimize tissue damage and provide adequate tissue

perfusion and oxygenation, proper nutrition and moist wound healing environment to restore the anatomical continuity and function of the affected part (Pierce and Mustoe, 1995). More than 80% of the world's population still depends upon traditional medicines for various skin diseases (Priya *et al.*, 2002). Many of the synthetic drugs currently used for the treatment of wounds are not only expensive but also pose problems such as allergy, drug resistance etc and this situation has forced the scientists to seek alternative drugs. Various plant species have served as a source of medicine for people all over the world, for years plant is one of the most intense areas of natural product research yet the field is far from being exhausted. Today, nearly 88% of the global populations turn to plant derived medicines as their first line of defence for maintaining health and combating diseases (Chopra *et al.*, 1956). Plants and their extracts have immense potential for the management and treatment of wound. The phyto-medicine for wound healing are not only cheap and affordable but are also purportedly safe as hypersensitive reactions are rarely encountered with the use of these agents. Many medicinal plants are claimed to be useful for wound healing in the traditional system of medicine though their mechanism of action and efficacy have not been evaluated scientifically. *Coccinia grandis* (family: Cucurbitaceae) also known as Ivy gourd. It is a fast growing ivy gourd which may grow up to four inches per day. Plant is used as a laxative. It is used internally in the treatment of gonorrhoea. Aqueous and ethanolic extracts of the plant have shown hypoglycaemic principles. *Coccinia grandis* native range includes Africa and Asia, India, China, Indonesia, Malaysia etc. We can use all body parts for medicinal purpose. So, it can be used in hypoglycaemia, as anti-oxidant, as immune grower etc. (Shaheen *et al.*, 2009).

* Corresponding Author

Email: deepubandarupalli@gmail.com

Contact: +91-9885250281

Received on: 02-03-2012

Revised on: 08-07-2012

Accepted on: 10-07-2012

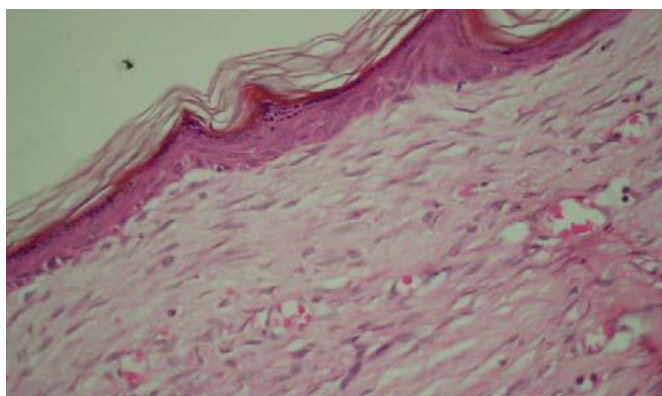


Figure 1: Control (H&E 400x) showing well formed but thick granular cell layer, the underlying dermis contains deposited collagen fibers with minimal inflammation

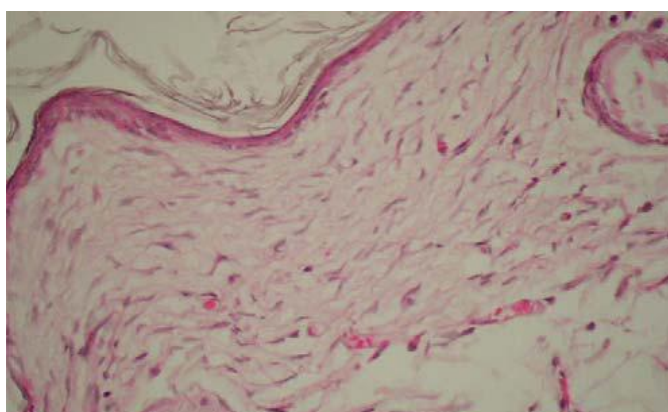


Figure 2: Animals treated with *Coccinia grandis* (H&E 400x) showing thin well-formed epidermis with hair follicle formation in the dermis and no inflammatory cells

This study was aimed to evaluate the Wound healing activity of *Coccinia grandis*.

MATERIALS AND METHODS

Inbred house albino and wistar rats of either sex were used in the study. The range of the weight of the animals is between 200-250g. They were housed individually in standardized environmental conditions. All the animals were provided with food ad libitum.

Plant Material Extraction

Bark of *Coccinia grandis* was collected from the village of vadlamudi, Guntur district, AP India. They were shade dried and coarsely powdered. The powdered material was placed in Soxhlet extractor and it is extracted with chloroform. The extract is evaporated and the dried residue i.e; drug is collected.

Phytochemical Screening

Various chemical tests were performed to identify the phytochemical constituents present in the chloroform extract of *Coccinia grandis*.

Drug Formulations

The chloroform extract of *Coccinia grandis* was formulated as 1%w/w and 4%w/w ointments respectively. These ointments were prepared by incorporating 1g and 4g of drug respectively into 100g of simple oint-

ment base. The standard drug used for wound healing activity was Nitrofurazone 0.2%w/w.

STUDY PROTOCOL

For each model 4 groups were used. Each group consists of 5 animals.

Group 1, 2, 3, 4 – Served as control, standard, treatment groups receiving 1% & treatment groups receiving 4% ointment respectively for Incision wound model.

Group 5, 6, 7, 8 – Served as control, standard, treatment group receiving 1% & treatment groups receiving 4% ointment respectively for Excision wound model.

Group 9, 10, 11, 12 – Served as control, standard, treatment groups receiving 1% & treatment groups receiving 4% ointment respectively for Dead space wound model.

TREATMENT SCHEDULE

Chloroform extracts of *Coccinia grandis* were mixed with ointment base and applied once a day to experimental animals to wounds until they were cured.

PREPARATION OF ANIMALS

The selected animals were individually caged after depilation of the selected area a day prior to experimentation for excision and resutured incision wound

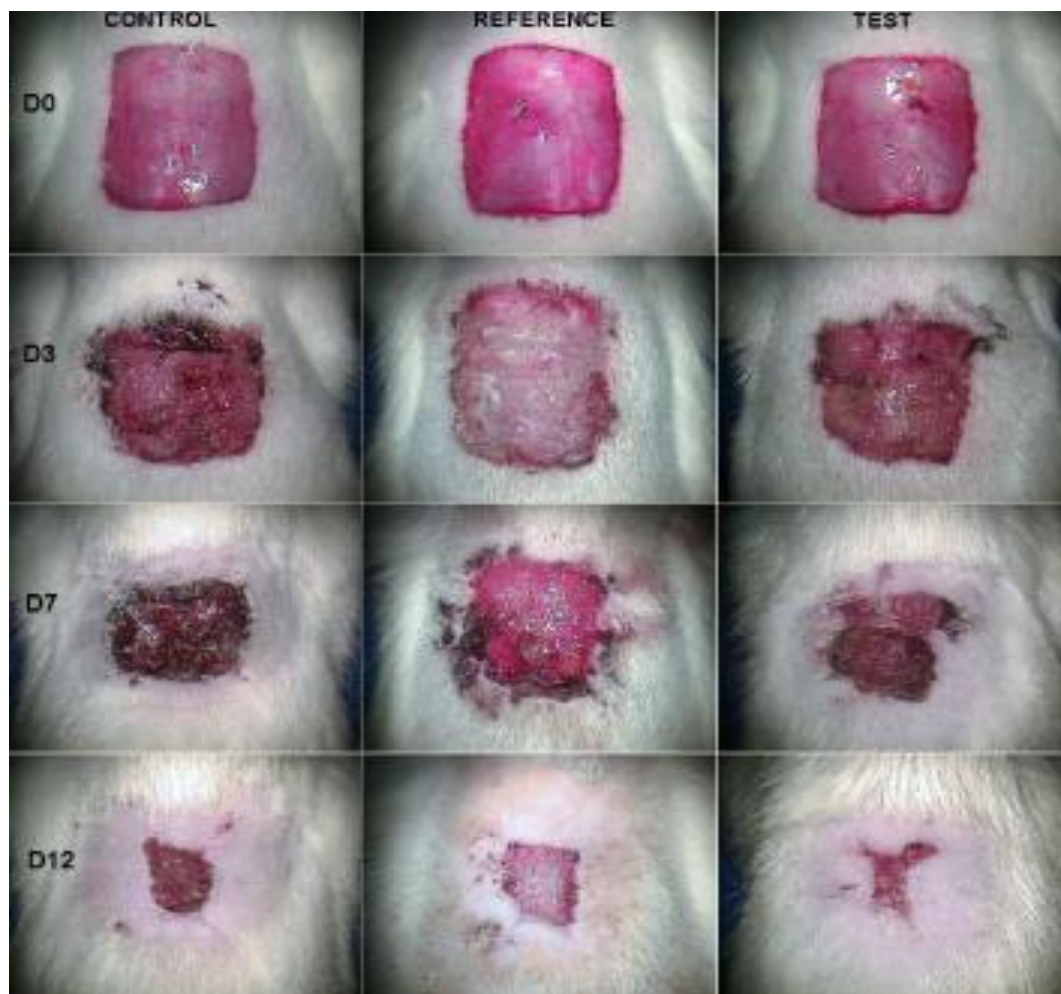


Figure 3: Appearance of wound healing in day 0, 3, 7&12

models. All the animals were fasted over night. The wound infliction is done aseptically under light ether anesthesia.

WOUND MODELS

INCISION WOUND MODEL

Two, 6-cm long paravertebral incisions were made through the full thickness of the skin on either side of the vertebral column of the rat (Lee KH, 1968). Wounds were closed with interrupted sutures, 1 cm apart. The sutures were removed on the seventh day. Wound-breaking strength was measured in anesthetized rats on the tenth day after wounding (Morton JJP et al., 1972).

EXCISION WOUND MODEL

A circular skin piece of full thickness (approximately 500 mm²) was removed from a predetermined dorsal area (Neuman et al., 1950). The wounds were traced on 1- mm² graph paper on the day of wounding and subsequently on alternate days until healing were complete. Changes in the wound area were calculated, giving an indication of the rate of wound contraction. The number of days required for falling of the eschar without any residual raw wound was determined as the period of epithelisation. The following Figure-3

represents the appearance of wound healing in day-0, 3, 7&12.

The degree of wound healing was calculated using the formula:

$$\text{Percentage closure} = 1 - A_d/A_0 \times 100$$

Where A_d = wound area on corresponding days; A_0 = wound area on zero day.

Histopathological studies

A section of the granuloma tissue was subjected to histopathological examination to determine the pattern of lay-down for collagen using two special stains. Figure 1 & Figure 2 represents the sections of granuloma tissue.

DEAD-SPACE WOUND MODEL

These wounds were created by implanting two polypropylene tubes (0.5 cm × 2.5 cm each), One on either side, in the lumbar region on the dorsal surface of each rat. On the tenth post wounding day, the granuloma tissue formed on the implanted tubes was dissected out carefully. The tissue was used for the determination of tensile strength (Neuman et al., 1950) after which it was dried in an oven at 60 °C for 24 h and the dry weight noted. The acid hydrolysate of the dry tis-

Table 1: Results for phytochemical screening

1	TEST FOR CARBOHYDRATES	
a	Molish's test	+
b	Fehling's test	+
c	Benedict test	+
2	TEST FOR FATS AND OILS	
a	Solubility test	+
3	TEST FOR PROTEINS	
a	Xanthoprotein test	+
b	Biuret test	+
4	TEST FOR STEROIDS	
a	Salkowski reaction	+
b	Liebermann's reaction	+
c	Liebermann-Burchard reaction	+
5	TEST FOR TANNINS	
a	Lead acetate solution	+
b	5% Ferric chloride solution	+
6	TEST FOR ALKALOIDS	
a	Dragendorff's test	+
b	Mayer's test	+
c	Hager's test	+
d	Wagner's test	+
7	TEST FOR CARDIAC GLYCOSIDES	
a	Baljet's test	
b	Legal's test	
c	Liebermann's test	
8	TEST FOR ANTHRAQUINONE GLYCOSIDES	
a	Borntragers test	
b	Modified Borntragers test	
9	TEST FOR SAPONIN GLYCOSIDES	
a	Foam test	
b	Hemolytic test	
10	TEST FOR FLAVANOIDS	
a	Schinoda test	+
b	Alkaline test	+

Table 2: Effect of CE of CG on tensile strength in incision wound model

GROUP	TENSILE STRENGTH (G ± SEM)
CONTROL	168±19.747
NFZ	228.8±6.851
CG 1%	306.4±32.664***+
CG 4%	410.8±15.564***++xx

Values are expressed as Mean ± SEM (n=5); *(P<0.001) Vs control group; +(P<0.001) Vs NFZ group; x (P<0.01) Vs CG 1%

sue was used for the estimation of hydroxyproline content in the tissue (Beauchamp et al., 1971).

STATISTICAL ANALYSIS

All values were expressed as Mean ± SEM. The data was analysed using analysis of variance followed by student T-test. In all tests, the criterion for statistical significance was P<0.05.

RESULTS AND DISCUSSION

Phyto-constituents were identified by phytochemical screening. Table-1 gives information about phyto-

chemical screening. The preliminary phyto-chemical screening of the chloroform extract of *coccinia* showed the presence of carbohydrates, fats, oils, proteins, tannins, phenolic compounds, saponins, resins, flavanoids. Wound healing is a step wise process, which consists of different phases such as haemostasis, inflammation, proliferative, remodelling and maturation phase (Y.Shivhare et al., 2010).The three different models were used in the present study to assess the wound healing activity of chloroform extract of *coccinia grandis*. The standard drug nitrofurazone is used to assess the healing potency of crude drug. Plants are the store

Table 3: Effect of CE of CG on wound closure and epithelialization in excision wound model

% OF CLOSURE OF EXCISION WOUND AREA						
GROUPS	DAY2	DAY 4	DAY 6	DAY 8	DAY10	EPITHELIALIZATION PERIOD
CTRL	3.2±0.734	13.6±1.122	22.4±0.927	41.2±0.800	58.4±0.509	20.6±0.400
NFZ	4.6±0.244	20±0.707	30.0±0.316	53.2±2.177	70±1.789	17.2±0.583
CG 1%	8±0.836**+	24.4±3.219*	51±3.536***++	80.6±1.939* **+++	93.6±1.030* **+++	12.6±0.400***+++
CG 4%	9±1.049** *++	37.6±3.516*** +++xx	68±5.950* **+++x	91.4±1.208* **+++xx	97.8±0.734* **+++	10.6±0.400***+++x

Values are expressed as Mean ± SEM (n=5)

***(p<0.001) Vs control group, **(p<0.01) Vs control group, *(p<0.05) Vs control group

+++ (p<0.001) Vs NFZ group, ++ (p<0.01) Vs NFZ group, + (p<0.05) Vs NFZ group

xx (p<0.01) Vs CG 1%, x (p<0.05) Vs CG 1%

Table 4: Effect of chloroform extract of *coccinia grandis* on hydroxyproline content in dead space wound model

GROUPS	DRY WEIGHT OF GRANULATION TISSUE	HYDROXYPROLINE (µG/ML)	
		2 ND DAY	10 TH DAY
CONTROL	0.549±0.014	1.088±0.308	4.748±1.232
NFZ	0.61±0.030	4.742±0.211	11.968±0.864
CG 1%	0.737±0.017***++	10.814±0.233***+++	14.208±0.628***
CG 4%	1.349±0.213***+++xx	13.762±0.245***+++xxx	23.492±1.782***+++xxx

Values are expressed as Mean ± SEM (n=5)

***(p<0.001) Vs control group

+++ (p<0.001) Vs NFZ group, ++ (p<0.01) Vs NFZ group

xxx (p<0.001) Vs CG 1%, xx (p<0.01) Vs CG 1%

houses for the variety of phytochemical constituents (H.M.Kumaraswamy et al., 2007). The process of healing is promoted by various active principles like triterpenes, alkaloids, flavanoids (Shukla et al., 1999). Table-2 shows effect of Chloroform extract of *Coccinia grandis* on Tensile strength in Incision wound model. The 4% treatment group served animals has shown significant (p<0.001) wound healing activity when compared to control and standard groups. Increasing in breaking strength of NFZ-ointment treated animals shows improved collagen migration by increased cross linking. Wound contraction is defined as the centripetal movement of the edges of a full thickness wound in order to promote seal of the defect (Peacock, 1984). Table-3 shows effect of Chloroform extract of *Coccinia grandis* on Wound closure and Epithelialisation in Excision wound model and Table-4 shows effect of Chloroform extract of *Coccinia grandis* on Hydroxyproline content in Dead space wound model. Both Table-3 and Table-4 has shown significant (p<0.001) wound healing activity when compared to control and standard groups respectively. The rate of wound contraction was less in control and standard groups when compared to SA-ointment treated animals increase in breaking strength of CG ointment treated animals shows improved collagen migration by cross linking. Granulation tissue formed in the final part of the pro-

liferative phase is primarily composed of fibroblasts, collagen, edema & new small blood vessels. Collagen is a major compound that strengthens extracellular tissue and is composed of amino acids, hydroxyproline, used as a biomarker for tissue collagen (Kumar et al., 2006). In the present study, (Table-4) hydroxyproline estimation has shown increased levels in the 4% treated groups and also there is a significant (P<0.001) increase in the granulation tissue. The wound healing activity of this medicinal plant is attributed to the active constituents present in it. Flavanoids reduce lipid peroxidation by preventing or slowing the onset of cell necrosis and improves vascularity (Tsuchiya et al., 1996). Plant products are shown to possess good therapeutic potential as anti-inflammatory agents and graduate wound healing, due to the presence of active terpenes, alkaloids and flavanoids (Fleischner, 1985), tannins (Ya et al., 1988) and triterpenoids (Scortichini and Pia Rossi, 1991) are known to magnify wound healing process. These active constituents promote the process of wound healing by increasing the viability of collagen fibres, by increase in the strength of collagen fibres either by increasing the circulation or by preventing the cell damage or by promoting the DNA synthesis (Getie et al., 2002).

CONCLUSION

The results of the present study revealed that the phytoconstituents carbohydrates, fats and oils, tannins, resins and phenolic compounds, alkaloids, saponins and flavonoids are known to avail wound healing activities. Any one of the observed phytochemical constituents present in *Coccinia grandis* may be responsible for the wound healing activity. This study shows that *Coccinia grandis* has wound healing effect when formulated as ointment and could therefore explain the success sores, boils and wounds.

ACKNOWLEDGEMENTS

The authors are thankful to Vignan college of Pharmacy for providing necessary facilities and for constant encouragement.

REFERENCES

- Abo A, Olugbuyro J A O, amakindes A. Anti-infective and Wound healing properties of *Flabellaria paniculata*. J of Biomedical Res 2004;7:85-87.
- Beauchamp C, Fridovich I Superoxide dismutase: Improved assays and assay applicable to acrylamide gels. Anal Biochem 1971; 44: 276-287
- Begum D, Nath SC. 2000. Ethnobotanical review of medicinal plants used for skin diseases and related problems in Northeastern India, Journal of Herbs. Spices and Medicinal Plants 7: 55-93.
- Buffoni F, Bancheli G, Cambi S, Ignesti G, Irisind R, Raimondi L.1993. Skin wound healing some biochemical parameters in Guinea pig. J Pharmaceutics and Pharmacology 45: 784-790. Glynn LE. 1981. The pathology of scar tissue formation. In: Glynn LE, Handbook of Inflammation. Volume 3. Elsevier North Holland Biomedical Press. Amsterdam. P 120-128.
- Chopra, RN, Nayar SL, Chopra IC. Glossary of Indian Medical Plants. CSIR, New Delhi, 1956.
- Coccinia grandis* as medicinal herb in INDIA: Natural occurrence, Traditional medicinal knowledge and trade (<http://www.botanical.com/site/column>)
- Coccinia grandis*- herb information ([http:// www. holisticonline.com/herbal-Med/-herbs h120.htm](http://www.holisticonline.com/herbal-Med/-herbs h120.htm))
- Franz, M.G., D.L Steed and M.C Robson, 2007 optimizing healing of the acute wound by minimizing complications. Curr.Probl.Surg., 44:691-763.
- Kumara Swamy H.M, V. Krishna, K. Shankaramurthy Wound healing activity of emblein isolated from the ethanolic extract of the leaves of *Embleia ribens* Burn journal of Ethnopharmacology 109(2007)529-534.
- Lee KH Studies on the mechanism of action of salicylates II. Effects of Vitamin A on Wound Healing retardation action of aspirin. J Pharm Sci 1968; 57: 1238
- Li, J., J. Chen and R.Kirsner, 2007. Pathophysiology of acute wound healing. Clin. Dermatol., 25:9-18
- M Ali. Pharmacognosy, CBS Publishers & Distributors, New Delhi.2008;668-669.
- Madden, J.W. and E.E Jr. Peacock, 1968. Studies on the biology of collagen during wound healing. I. Rate of collagen synthesis and deposition in cutaneous wounds of the rat. Surgery, 64:288-294
- Martin P. 1997.Wound healing aiming for perfect skin degeneration. Science. 75-81p.
- Morton JJP, Malone HH Evaluation of vulnerary activity by open wound procedure in rats, Arch Int Pharmacodyn. 1972; 196: 117
- Neuman RE, Logan MA. The determination of collagen and elastin in tissues. J Biochem 1950; 186: 549
- Peacock EE. Contraction.in; Wound repair, 1994; 3rd edition, 1197;3-14.
- Pierce GF, Mustoe TA.1995. Pharmacologic enhancement of wound healing. Annual Review of Medicine 46: 467-481.
- Priya, K.S., Gnanamani, A., Radhakrishnan, N., Babu, M., 2002. Healing potential of *Datura alba* on burn wounds in albino rats. Journal of Ethnopharmacology 83, 193-199.
- Sanjay. Prahald. Umachigi, G.S.Kumar, K.N.Jayaveera, K.V.Kishor Kumar, C.K.Ashok kumar R.Dhanapal (2007) antimicrobial, wound healing and anti-oxidant activity of *Anthocephalous cadamba*. Afr.J.Trad. CAM 2007;4(4); 481-487
- Shaheen S J, Bolla K, Vasu K, & Charya MA S. Antimicrobial activity of the fruit extracts of *Coccinia indica* African J of Biotech, 24(2009) 7073-7076.
- Shukla A, rasik AM Jain GK, Shankar R, Kulshershtha Dk, Dhawan BIV 1999.invitro and invivo wound healing activity of asiaticoside isolated from *Centilla asiatica* journal of Ethanopharmacology 615: 1-11.
- Stadelamn, W.k., A.G. Diginis and G.R.Tobin., 1998. Physiology and healing dynamics of chronic cutaneous wounds. Am.J. Surg 176;265-385
- Strodtbeck, F., 2001 physiology of wound healing. Newborn infants Nurs. Rev.,:43-52.